




**University of Zagreb
Faculty of Veterinary Medicine**

**23rd – 24th
February 2026
Zagreb, Croatia**

**11th International
Congress
Veterinary Science
and Profession**

**BOOK
OF
ABSTRACTS**





11TH

**INTERNATIONAL
CONGRESS**

***VETERINARY SCIENCE
AND PROFESSION***

FEBRUARY 23RD – 24TH, 2026

GOLD SPONSOR



**Boehringer
Ingelheim**



a PHOENIX company

SILVER SPONSOR



BRONZE SPONSORS



AGROPROTEINKA



PHILIPS



SPONSORS



medical intertrade



DONORS



ORGANISER

University of Zagreb
Faculty of Veterinary Medicine

ORGANISING COMMITTEE

President:

Jelena Gotić

Vice-presidents:

Kim Korpes

Maja Lukač

Congress secretary:

Magdalena Kolenc

Local Organising Committee:

Gordana Gregurić Gračner, Martina Lojkić, Nino Maćešić, Hrvoje Capak, Martina Crnogaj, Marko Pećin, Magda Sindičić, Dražen Đuričić, Doroteja Huber, Maša Efendić, Liča Lozica, Aneta Piplica, Valentina Plichta, Lada Radin, Juraj Šavorić, Ira Topličanec, Iva Zečević, Petra Bratić, Ana Javor, Marta Kiš, Katarina Miljak, Elizabeta Pongrac, Željana Klječanin Franić

International Organising Committee:

Tibor Bartha, Breda Jakovac Strajn, Danijela Kirovski, Atila Kos, Milan Maletić, Jana Mojžišova, Lazo Pendovski, Muhamed Smajlović, Ivan Stančić, Peter Sotonyi, Martin Tomko, Petra Winter

Scientific Committee:

President: Marko Samardžija

Ivan Alić, Maja Belić, Nika Brkljača Bottegaro, Ivan Folnožić, Darko Grden, Luka Krstulović, Marija Lipar, Maja Maurić Maljković, Sven Menčik, Tomislav Mikuš, Matko Perharić, Vladimir Stevanović, Marin Torti, Ksenija Vlahović, Dražen Vnuk, Zoran Vrbanac, Ana Shek Vugrovečki, Ivan Zemljak, Iva Šmit, Ivan Conrado Šoštarić, Ivona Žura Žaja

ISSN 2806-8564

All abstracts published in this Book of Abstracts have been reviewed by an international scientific board.

IMPRESSUM

Editors

Jelena Gotić, Magdalena Kolenc, Kim Korpes

Reviewers

Jasna Aladrović, Ivan Alić, Maja Belić, Valerija, Benko, Nika Brkljača Bottegaro, Miljenko Bujanić, Ivan Butković, Hrvoje Capak, Martina Crnogaj, Petra Dmitrović, Martina Đuras, Dražen Đuričić, Maša Efendić, Ivan Folnožić, Tomislav Gomerčić, Jelena Gotić, Željko Gottstein, Damjan Gračner, Gordana Gregurić Gračner, Darko Grden, Josipa Habuš, Danijela Horvatek Tomić, Dorotea Huber, Ines Jović, Filip Kajin, Ivana Kiš, Marta Kiš, Miljenko Konjačić, Dean Konjević, Petar Kostešić, Magdalena Kolenc, Kim Korpes, Anita Kraljević, Gabrijela Jurkić Krsteska, Luka Krstulović, Nada Kučer, Josipa Kuleš, Andrea Gudan Kurilj, Marija Lipar, Liča Lozica, Maja Lukač, Branka Beer Ljubić, Maja Maurić Maljković, Nino Mačešić, Marija Mamić, Franjo Martinković, Sven Menčik, Dinko Novosel, Mario Ostović, Lana Pađen, Marko Pećin, Matko Perharić, Selma Pintarić, Aneta Piplica, Valentina Plichta, Ivana Sabolek, Krešimir Severin, Magda Sindičić, Vladimir Stevanović, Josip Šavorić, Nikolina Škvorc, Iva Šmit, Ivan Conrado Šoštarić, Zrinka Štritof, Ira Topličanec, Marin Torti, Romana Turk, Nenad Turk, Valentina Vidranski, Dražen Vnuk, Zoran Vrbanac, Mirta Vučković, Ana Shek Vugrovečki, Lidija Medven Zagradišnik, Nevijo Zdolec, Iva Zečević, Ivona Žura Žaja

Publisher

Faculty of Veterinary Medicine, University of Zagreb
10 000 Zagreb, Heinzelova 55

Dear colleagues,

It is my great honor to officially open the 11th International Congress *Veterinary Science and Profession 2026*. Designing the program for a non-specialist congress, one that brings together the entire veterinary profession and all fields of veterinary science, is no simple task. This year, we set our ambitions high.

In number, our efforts look like this: we invited 28 speakers and round-table participants. We are joined by approximately 250 veterinarians and 150 students attending free of charge—around 400 participants in total. We organized 55 hours of CPD workshops for 97 veterinarians across 11 workshops, as well as six free workshops for 70 students. We prepared five thematic sections with invited lecturers, experts in their respective fields, who will share the latest scientific and professional insights. We have placed special emphasis on young scientists, through short oral communications, poster presentations, and tomorrow's PhD Day, which continues the tradition of supporting early-career researchers. This year marks the introduction of a new Projects Section, bringing together all ongoing research conducted at our Faculty and offering a clearer picture of the breadth and diversity of our academic activities. In addition, we have organized three round tables addressing key issues currently facing the veterinary profession.

Our heartfelt thanks go to our sponsors. We are especially grateful to our gold sponsor, Boehringer Ingelheim, as well as Phoenix Farmacija, and to all our other sponsors and donors. We also extend our sincere appreciation to our volunteer students, who once again serve as our strongest technical support, and to all members of the Organizing and Scientific Committees.

Our profession is extraordinarily broad, yet we are united by a shared mission: to serve animals and safeguard their health. Along this journey, we often prioritize the well-being of others over our own. We are reminded daily that in order to care for others, we must also care for ourselves.

For this reason, this year we have dedicated part of the congress program to the well-being and mental health in veterinary medicine. Our aim is not only to recognize the challenges we face but also to equip ourselves with tools that help us become healthier, stronger, and better professionals.

Assoc. Prof. Jelena Gotić
President of the Organising Committee

Acknowledgements

The Congress and the production of these proceedings were supported by the following organisations:

Under the auspices of

President of the Republic of Croatia

Mayor of the City of Zagreb

Gold Sponsor

BOEHRINGER INGELHEIM RCV GMBH & CO KG

Silver Sponsor

MIDES MEDTEH d.o.o.

Bronze Sponsor

AGROPROTEINKA d.d.

ARBOR MEDICAL d.o.o.

ARTHREX ADRIA d.o.o.

ROYAL CANIN LJUBLJANA d.o.o.

PURINA

Sponsors

GENERA d.d.

MEDICAL INTERTRADE d.o.o.

SONIMED d.o.o.

3B SCIENTIFIC EUROPE Kft.

MYLAV S.r.l.

REPROMAT-ZAGREB d.o.o.

VETERINARSKA STANICA KRIŽEVCI d.o.o.

MÖLNLYCKE HEALTH CARE ADRIA d.o.o.

MEDICAL CENTAR d.o.o.

B.I.G. B.L.U.E. d.o.o.

VET CONSULTING d.o.o.

VOXA

LABOKLIN GMBH & CO. KG

Donors

ATLANTIC GRUPA d.d.

BELJE PLUS d.o.o.

DDL ZAGREB d.o.o.

FRANCK d.d.

IRIS FARMACIJA d.o.o.

LOHMANN & RAUSCHER d.o.o.

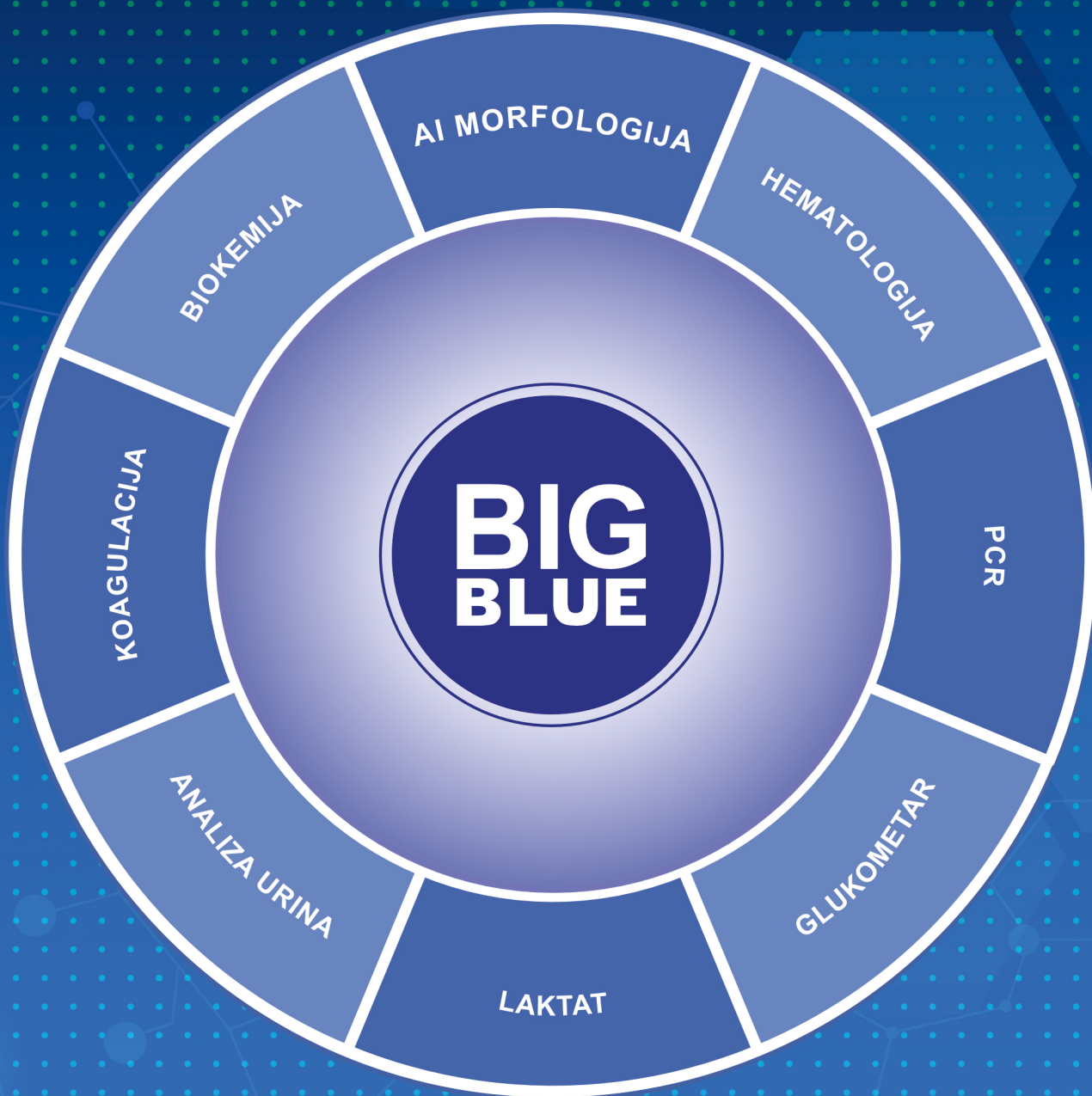MACAN d.o.o.

MEDICINSKA NAKLADA d.o.o.

TURISTIČKA ZAJEDNICA GRADA ZAGREBA

Additional support received from

THE FACULTY OF VETERINARY MEDICINE, UNIVERSITY OF ZAGREB



**KOMPLETNA DIJAGNOSTIKA
ZA VETERINARSKJE AMBULANTE**


B.I.G. B.L.U.E. d.o.o.

www.bigblue.hr | info@bigblue.hr | 052/218518, 052/218528 |



IDEXX

Relentless innovation.





ReproVet







PROGRAMME

DAY 1 – FEBRUARY 23, 2026

Registration and Opening (Main Lecture Hall, building 1)

- 08:00 – 09:00 Registration (building 1)
09:00 – 09:15 Congress Opening
09:15 – 09:45 Keynote Lecture - **Petra Agthe**: Behind the Stethoscope: The Human Side of the Veterinary Profession (Main Lecture Hall, building 1)
09:45 – 10:15 Coffee Break (building 1)

Small Animal Section (Main Lecture Hall, building 1)

- 10:15 – 10:45 Invited Lecture - **Erika Furman**: FIP – Diagnostic possibility in the In-House Lab
10:45 – 11:15 Invited Lecture - **Filip Kajin**: Neurologic Form of Feline Infectious Peritonitis – A Brain Teaser
11:15 – 11:45 Invited Lecture - **Katharina Buchta**: FIP from challenge to cure – current treatment options, therapy monitoring and potential side effects (Speaker arrival supported by LABOKLIN)
11:45 – 12:00 Discussion
12:00 – 12:45 Lunch (Students' Hall, building 2)

12:45 – 13:15 **Elizabeta Pongrac**: Beyond insulin: SGLT2 inhibitors in feline diabetes mellitus (Boehringer Ingelheim RCV, sponsor lecture)
13:15 – 13:45 **Davorin Lukman**: How serious a problem is the MDR1 genetic defect in everyday practice? (LABOKLIN, sponsor lecture)
13:45 – 14:15 Invited Lecture - **Veljko Turković**: Building a Veterinary Practice That Works. Idea. Strategy. Team. Client Care.

Short Communication with Discussion

- 14:15 – 14:25 *Chronic oronasal fistula in a dog associated with a mineralised nasal foreign body – a case report* (Mirta Vučković, Mirta Paić Radovniković, Marija Mamić)
14:25 – 14:35 *Epidemiological, clinical, and laboratory characteristics of adrenal tumors in dogs and cats admitted to the Clinic for Internal Diseases, Faculty of Veterinary Medicine, University of Zagreb (January 2022 – October 2025): a retrospective study* (Katarina Marjanović, Elizabeta Pongrac, Magdalena Bogović, Branko Petričević, Iva Šmit, Martina Crnogaj, Marin Torti)
14:35 – 14:45 *Gallbladder Mucocele in Dogs: A Retrospective Study of Clinical and Histopathological Features* (Elizabeta Pongrac, Branko Petričević, Magdalena Bogović, Katarina Marjanović, Maša Efendić, Ivana Kiš, Martina Crnogaj)
14:45 – 14:55 *Significance of Clostridium perfringens netE and netF toxin genes in dogs with acute diarrhea* (Vanda Dučić, Vesna Mojčec Perko, Iva Benvin, Josipa Habuš, Zrinka Štritof, Vladimir Stevanović, Matko Perharić, Iva Zečević, Krešimir Martinković, Suzana Hađina)

- 14:55 – 15:05 *Quantitative shear-wave elastography of the canine prostate: a comparative clinical assessment of healthy tissue, intraprostatic cysts and benign prostatic hyperplasia* (Ivan Tomić, Maša Efendić, Ivan Butković, Juraj Šavorić, Tugomir Karadjole, Martina Lojkić)
- 15:05 – 15:15 Discussion
- 15:15 – 16:00 Poster Session and Coffee Break (Hall of the Reproduction and Obstetrics Clinic - building 8)

Equine Section (Clinical Lecture Hall, building 9)

- 10:15 – 10:45 Invited Lecture - **Nika Brkljača Bottegaro**: Equine Wound Management
- 10:45 – 11:15 Invited Lecture - **Matko Perharić**: Tetanus in Horses: When a Wound Becomes a Danger and Prevention is Key
- 11:15 – 11:45 Invited Lecture - **Juraj Šavorić**: Reproductive system injuries in horses
- 11:45 – 12:00 Discussion
- 12:00 – 13:00 Lunch (Students' Hall, building 2)

Short Communication with Discussion

- 13:00 – 13:10 *Physal fracture of the lateral epicondyle of the humerus in a foal with tetanus – a case report* (Katarina Miljak, Jelena Gotić, Darko Grden, Petra Bratić, Matko Perharić, Lidija Medven Zagradišnik, Nika Brkljača Bottegaro)
- 13:10 – 13:20 *Persistent hyaloid artery and coloboma in a horse – a case report* (Katarina Miljak, Antea Rački, Nika Brkljača Bottegaro, Marija Mamić)
- 13:20 – 13:30 *Rupture of the longus capitis muscle in seventeen horses* (Luka Špelic, Sonja Berger, Rosa Barsnick, Vicky Frisch)
- 13:30 – 13:40 *First evidence of Theileria equi infection in apparently healthy donkeys from Croatia* (Nika Konstantinović, Ema Gagović, Jelena Gotić, Daria Jurković-Žilić, Antun Kostelić, Gordan Šubara, Relja Beck)
- 13:40 – 13:50 *Molecular prevalence of equine piroplasmiasis in Istria region* (Nika Konstantinović, Franka-Emilija Čulina, Nika Delić, Ema Gagović, Jelena Gotić, Daria Jurković-Žilić, Antun Kostelić, Dora Višal, Relja Beck)
- 13:50 – 14:00 Discussion
- 15:00 – 16:00 Poster Session and Coffee Break (Hall of the Reproduction and Obstetrics Clinic - building 8)

Project Presentations (Lecture Hall of the Department of Microbiology and Infectious Diseases with Clinic, building 4)

- 14:00 – 14:15 *Investigation of brain development and genes in Down syndrome* (Ante Plećaš, Sandra Kunštek, Ana Družeta, Anna Titova, Magdalena Palić, Krešimir Severin, Matija Horaček, Petra Šoštarić Mužić, Gillian Gough, Ivan Alić)
- 14:15 – 14:30 *Lighting the way towards in situ osteochondral regeneration through microextrusion and filamented light bioprinting (LUMINATE)* (Valentina Kos, Dražen Matičić, Kostešić, Mirta Vučković)
- 14:30 – 14:45 *Life Wild Wolf: a long-term conservation of wolves in human dominated landscapes of Europe – understanding wolf – dog interactions* (Josip Kusak, Dario Hipolito, Krešimir Severin, Maja Popović, Daniel Špoljarić, Lana Pađen, Magdalena Palić, Neška Vukšić Končevski, Andrea Solić)
- 14:45 – 15:00 *UNIC VIP project equine reproduction-educational and expert collaboration between Croatia and Belgium 2026-2028* (Nikica Prvanović Babić, Juraj Grizelj, Stefan Deleuze)
- 15:00 – 15:15 *Investigations of Extracellular Vesicles in Dogs and Subclinical Mastitis in Dairy Cows* (Vladimir Mrljak)
- 15:15 – 15:30 *Best practices and innovations for sustainable beekeeping (B-THENET Project)* (Ivana Tlak Gajger)
- 15:30 – 16:00 Guided Tour of the Educational and Archival Beekeeping Facility

Round Table (Main Lecture Hall, building 1)

- 16:00 – 17:30 Round Table – Challenges in veterinary practice today (Panelists: Petra Agthe, Andrea Ražić Pavičić, Veljko Turković, Ivan Zemljak)
- 17:30 – 18:00 **Andrea Ražić Pavičić** – Client Communication: How to Conduct Difficult Conversations (interactive lecture in Croatian)
- 18:00 – 21:00 **Welcome Reception** (Students' Hall, building 2)
- From 21:00 **VZS Party** (Students' Hall, building 2)

DAY 2 – FEBRUARY 24, 2026

Registration (Main Lecture Hall, building 1)

08:00 – 08:30 VZSRun – 5 km Pre-Congress Morning Run (Meeting point in front of building 1)

08:00 – 09:00 Registration (building 1)

Exotic and Wildlife Animal Section (Main Lecture Hall, building 1)

09:00 – 09:30 Invited Lecture - **Pavel Kvapil**: From Zoo to the Wild: Veterinary Experience with Wild Carnivores

09:30 – 10:00 Invited Lecture - **Joško Račnik**: Anesthesia and Surgery in African Pygmy Hedgehogs

10:00 – 10:15 Discussion

10:15 – 10:30 Coffee Break

Short Communication with Discussion

10:30 – 10:40 *Evaluation of the bunny wrap method restraint technique for CT imaging in rabbits: a one-year experience* (Ana Javor, Gabrijela Jurkić Krsteska, Barbara Mratović, Petar Krolo, Hrvoje Capak, Zoran Vrbanac)

10:40 – 10:50 *Eurasian lynx (*Lynx lynx*) mortality in Croatia in the 2013 – 2023 period* (Matea Kulušić, Magda Sindičić, Ira Topličanec, Vedran Slijepčević, Josip Kusak, Tomislav Gomerčić)

10:50 – 11:00 *Secondary nutritional hyperparathyroidism in a captive Chinese striped-neck* (Helena Potet, Siniša Faraguna, Ana Javor, Josip Miljković, Dražen Đuričić)

11:00 – 11:10 *First insights into the molecular diversity of *Dipylidium* and *Joyeuxiella* in Croatia and Bosnia and Herzegovina* (Ana Šikić, Ema Gagović, Šimun Naletilić, Daria Jurković Žilić, Adnan Hodžić, Amer Alić, Magda Sindičić, Relja Beck)

11:10 – 11:20 *Ovarian cyst and follicle development in a female peach-faced lovebird (*Agapornis roseicollis*) following salpingectomy* (Matea Kapitanić, Maja Lukač, Emanuel Budicin, Dražen Đuričić)

11:20 – 11:30 *Clinical application of photobiomodulation therapy in wildlife rehabilitation at WildRescueVef Rescue Centre* (Kristina Popović, Tvrtko Mataušić, Dražen Đuričić, Maja Lukač)

11:30 – 11:40 Discussion

12:00 – 13:00 Lunch (Students' Hall, building 2) and Poster Session (Hall of the Reproduction and Obstetrics Clinic - building 8)

Veterinary Public Health Section (Lecture Hall of the Department of Microbiology and Infectious Diseases with Clinic, building 4)

- 09:00 – 09:30 Invited Lecture - **Branko Velebit**: Methods for Detection of Non-Cultivable Viruses in Foods
- 09:30 – 10:00 Invited Lecture - **Ivan Vičić**: Antimicrobial Resistance in Food-Producing Animals: Food Safety and One Health Approach
- 10:00 – 10:30 Invited Lecture - **Giuditta Tilli**: The delicate role of biosecurity in modern poultry production
- 10:30 – 10:45 Discussion
- 10:45 – 11:00 Coffee Break

Short Communication with Discussion

- 11:00 – 11:10 *Effects of the Freezing Process on the Physical and Chemical Properties of Beef from Different Breeds and Sexes* (Katarina Smolčić, Mladenka Vukšić, Željka Cvrtila, Tomislav Mikuš)
- 11:10 – 11:20 *Preliminary results on the prevalence of Salmonella spp. serovars in Croatia for 2025* (Lucija Hlebić, Lovran Peinović, Andrea Humski, Antonela Bagarić, Sanja Duvnjak, Maja Dopud, Dora Tomašković)
- 11:20 – 11:30 *Epidemiology and serotype diversity of Salmonella spp. in poultry and wildlife: implications for public health in Bosnia and Herzegovina* (Sajma Huremović, Selma Kunić, Dejana Krneta)
- 11:30 – 11:40 *Campylobacter occurrence in seabirds during the breeding season in Croatia* (Viktor Mašović, Biljana Ječmenica, Louie Taylor, Luka Jurinović)
- 11:40 – 11:50 Discussion
- 12:00 – 13:00 Lunch (Students' Hall, building 2) and Poster Session (Hall of the Reproduction and Obstetrics Clinic - building 8)

Round Table (Main Lecture Hall, building 1)

- 13:00 – 15:00 Round Table – Social and Humanistic Sciences in Higher Veterinary Education (Panelists: Ivana Franić, Snježana Kužir, Željana Klječanin Franić, Iva Lehunšek Panić, Jovana Ivanić, Marko Poletto, Željka Kamenov)

PhD Day (Vet Skill and Chill, building 6)

- 15:00 – 16:45 Round Table – Scandinavian model or monograph – the question now (Panelists: Alen Slavica, Vedrana Pšenica, Iva Benvin, Ivana Sabolek, Relja Beck)
- 17:00 – 18:00 Association Sentinel Uma – Workshop for PhD Students - *Mental Health, Burnout and Resilience in Academic and Professional Career (in Croatian)*

Farm Animal Section (Clinical Lecture Hall, building 9)

- 13:15 – 13:45 Invited Lecture - **Melanie Schären Bannert**: The Economics of Disease in Dairy Production – Why Investing in a Veterinarian Is of Value
- 13:45 – 14:15 Invited Lecture - **Cassandra Eibl**: Pain management in calves
- 14:15 – 14:45 Invited Lecture - **Harald Pothmann**: Monitoring Reproductive Performance and Fertility Problems in Dairy Cows
- 14:45 – 15:00 Discussion

Participant Presentations with Discussion

- 15:00 – 15:10 *Detection and genomic properties of unusual Rotavirus A strains of zoonotic porcine origin in humans* (Valentina Kunić, Vjekoslava Kostanić, Sara Špoljar, Marina Prišlin Šimac, Ksenija Kretonić, Dubravka Vuković, Tea Čuti, Draženka Vadla, Dragan Brnić)
- 15:10 – 15:20 *Brač sheep and its maternal origins: preliminary mitochondrial DNA findings* (Jasna Kusanović, Ivan Vlahek, Velimir Sušić, Maja Maurić Maljković)
- 15:20 – 15:30 *Melatonin treatment enhances post-thaw sperm function in French alpine bucks during the non-breeding season* (Ivona Žura Žaja, Ivan Butković, Velimir Berta, Hrvoje Valpotić, Marko Samardžija, Martina Lojkić, Dražen Đuričić, Suzana Milinković Tur, Vanja Lončarić, Stefani Fruk Šimunec, Anamaria Ružić, Silvijo Vince)
- 15:30 – 15:40 *Traumatic reticuloperitonitis in a three-year-old Holstein cow: a case report* (Petra Bratić, Darko Grden, Ivan – Conrado Šoštarić – Zuckermann, Jelena Gotić, Katarina Miljak, Goran Štibrić, Ivana Cvitaš)
- 15:40 – 15:50 Discussion

Congress Closing (Main Lecture Hall, building 1)

- 16:15 – 17:00 Congress Closing and Awards Ceremony

Table of Contents

ABSTRACTS	13
KEYNOTE LECTURE	14
BEHIND THE STETHOSCOPE: THE HUMAN SIDE OF THE VETERINARY PROFESSION	15
INVITED LECTURES	17
FIP – DIAGNOSTIC POSSIBILITY IN THE INHOUSE LABORATORY	18
NEUROLOGIC FORM OF FELINE INFECTIOUS PERITONITIS – A BRAIN TEASER	21
FIP FROM CHALLENGE TO CURE – CURRENT TREATMENT OPTIONS, THERAPY MONITORING AND POTENTIAL SIDE EFFECTS	22
BEYOND INSULIN: SGLT2 INHIBITORS IN FELINE DIABETES MELLITUS	24
HOW SERIOUS IS THE PROBLEM OF MDR1 GENE DEFECT IN EVERYDAY PRACTICE?	25
BUILDING A VETERINARY PRACTICE THAT WORKS. IDEA STRATEGY. TEAM. CLIENT CARE.	27
EQUINE WOUND MANAGEMENT	28
TETANUS IN HORSES: WHEN A WOUND BECOMES A DANGER AND PREVENTION IS THE KEY	30
REPRODUCTIVE SYSTEM INJURIES IN HORSES.....	32
CLIENT COMMUNICATION: HOW TO CONDUCT DIFFICULT CONVERSATIONS	33
FROM ZOO TO THE WILD – VETERINARY EXPERIENCE WITH WILD CARNIVORES.....	34
ANAESTHESIA AND SURGERY IN AFRICAN PYGMY HEDGEHOCKS	35
METHODS FOR DETECTION OF NON-CULTIVABLE VIRUSES IN FOODS	36
ANTIMICROBIAL RESISTANCE IN FOOD-PRODUCING ANIMALS: FOOD SAFETY AND ONE HEALTH APPROACH.....	39
THE DELICATE ROLE OF BIOSECURITY IN MODERN POULTRY PRODUCTION	40
THE ECONOMICS OF DISEASE IN DAIRY PRODUCTION – WHY INVESTING IN A VETERINARIAN IS OF VALUE	41
PAIN MANAGEMENT IN CALVES.....	43
MONITORING REPRODUCTIVE PERFORMANCE AND FERTILITY PROBLEMS IN DAIRY COWS	44
SMALL ANIMALS SESSION	46
ORAL PRESENTATIONS	46
CHRONIC ORONASAL FISTULA IN A DOG ASSOCIATED WITH A MINERALISED NASAL FOREIGN BODY - A CASE REPORT.....	47
EPIDEMIOLOGICAL, CLINICAL, AND LABORATORY CHARACTERISTICS OF ADRENAL TUMORS IN DOGS AND CATS: A SINGLE-CENTER RETROSPECTIVE STUDY (2022–2025).....	48
GALLBLADDER MUCOCELE IN DOGS: A RETROSPECTIVE STUDY OF CLINICAL AND HISTOPATHOLOGICAL FEATURES.....	49
SIGNIFICANCE OF <i>CLOSTRIDIUM PERFRINGENS NETE</i> AND <i>NETF</i> TOXIN GENES IN DOGS WITH ACUTE DIARRHEA	50
QUANTITATIVE SHEARWAVE ELASTOGRAPHY OF THE CANINE PROSTATE: A COMPARATIVE CLINICAL ASSESSMENT OF HEALTHY TISSUE, INTRAPROSTATIC CYSTS AND BENIGN PROSTATIC HYPERPLASIA	51
SMALL ANIMALS SESSION	52
POSTER PRESENTATIONS	52
A CASE OF PERSISTENT DECIDUOUS CANINE TOOTH IN A DOMESTIC CAT	53
COMPARATIVE ANALYSIS OF THREE VALIDATED DOG BEHAVIOUR AND PERSONALITY QUESTIONNAIRES: C-BARQ, DPQ, AND PANAS	54
A RETROSPECTIVE SURVEY ON CANINE INTRACRANIAL TUMORS BETWEEN 2015 AND 2025	55
<i>MODUS OPERANDI</i> OF DOG ATTACKS IN DIFFERENT SPECIES.....	56
SEROPREVALENCE OF <i>LEPTOSPIRA</i> SPP. IN CATS IN CROATIA	57
FATAL MULTIPLE CONGENITAL MALFORMATIONS IN A POMERANIAN PUPPY– A CASE REPORT... ..	58
CRANIOMANDIBULAR OSTEOPATHY IN TWO ALPINE DACHSBRACKS – A CASE STUDY	59

MAGNETIC RESONANCE IMAGING (MRI) SAFETY IN VETERINARY PATIENTS WITH RETAINED METALLIC PROJECTILES	60
EFFECTS OF AGE AND BODY WEIGHT ON SEMEN QUALITY IN DOGS.....	61
EFFECT OF PASSIVE SMOKING ON SOME HEMATOLOGICAL PARAMETERS AND FATTY ACID COMPOSITION IN DOGS – PRELIMINARY STUDY.....	62
ASSOCIATION BETWEEN EXPANSILE BONE LESIONS AND OLIGODONTIA IN DOGS AND CATS: A RETROSPECTIVE CT STUDY	63
PRIMARY STABILIZATION AND EMERGENCY MANAGEMENT OF TWO CATS FOLLOWING SMOKE INHALATION	64
EVALUATION OF COAGULATION PARAMETERS AS PROGNOSTIC INDICATORS IN CANINE HEATSTROKE.....	65
QUALITATIVE DETECTION OF ANTIBODIES AGAINST PARVOVIROSIS AND DISTEMPER IN DOGS ..	66
PERIRENAL URINOMA ASSOCIATED WITH UNILATERAL HYDRONEPHROSIS IN A CAT	67
SECONDARY NUTRITIONAL HYPERPARATHYROIDISM IN A KITTEN – A CASE REPORT	68
SEPTIC HEMOPERITONEUM CAUSED BY AIR RIFLE PROJECTILE INJURY IN A DOG: CLINICAL AND SURGICAL MANAGEMENT	69
ERYTHROID MYELODYSPLASTIC SYNDROME PROGRESSING TO SUSPECTED ACUTE MYELOBLASTIC LEUKEMIA IN A MAINE COON CAT	70
MULTIPLE MYELOMA IN A STAFFORDSHIRE TERRIER: A CASE REPORT	71
CT-ASSISTED DIAGNOSIS AND SURGICAL REPAIR OF A TRAUMATIC ORONASAL DEFECT IN A DOG- A CASE REPORT	72
FOCUSED EXTRACORPOREAL SHOCKWAVE THERAPY AND PHOTOBIOMODULATION IN THE REHABILITATION OF A DOG WITH BILATERAL SCAPULOHUMERAL OSTEOARTHRITIS: A CASE REPORT	73
FOLLOW YOUR GUT: INSIGHTS FROM SMALL ANIMAL GASTROINTESTINAL ENDOSCOPY	74
CONSIDERING TAURINE-RESPONSIVE MYOCARDIAL DYSFUNCTION DESPITE NORMAL BLOOD TAURINE: A CASE REPORT IN A WEIMARANER	75
MANAGEMENT OF FELINE STOMATITIS USING CLASS 4 LASER PHOTOBIOMODULATION	76
ECTOPIC PAROTID GLAND TISSUE IN THE DOG: A CASE REPORT	77
RELATIONSHIP BETWEEN CREATININE CONCENTRATION AND CHANGES IN SERUM METABOLOME IN BITCHES WITH PYOMETRA.....	78
ACID-BASE STATUS PARAMETERS OF HEPARINIZED VENOUS DOG BLOOD DURING STORAGE AT ROOM TEMPERATURE	79
INFLUENCE OF SHORT-TERM SERUM STORAGE IN SEPARATE TUBE ON ENZYMES ACTIVITY IN DOGS.....	80
DOES SHORT-TERM CANINE SERUM STORAGE ON GEL AFFECT CONCENTRATION OF DIAGNOSTICALLY IMPORTANT SUBSTRATES?	81
EQUINE SESSION	82
ORAL PRESENTATIONS	82
PHYSEAL FRACTURE OF THE LATERAL EPICONDYLE OF THE HUMERUS IN A FOAL WITH TETANUS – A CASE REPORT	83
PERSISTENT HYALOID ARTERY AND COLOBOMA IN A HORSE – A CASE REPORT	84
RUPTURE OF THE LONGUS CAPITIS MUSCLE IN SEVENTEN HORSES	85
MOLECULAR PREVALENCE OF EQUINE PIROPLASMOSIS IN ISTRIA REGION	86
FIRST EVIDENCE OF <i>THEILERIA EQUI</i> INFECTION IN APPARENTLY HEALTHY DONKEYS FROM CROATIA	87
EQUINE SESSION	88
POSTER PRESENTATIONS.....	88
BILATERAL GONADAL TERATOMA IN A LIPIZZANER COLT	89
INFECTIOUS ENDOCARDITIS IN A TWO-WEEK-OLD FOAL: CASE REPORT	90
ESOPHAGEAL OBSTRUCTION AS A POTENTIAL CLINICAL MANIFESTATION OF PITUITARY PARS INTERMEDIA DYSFUNCTION IN HORSES.....	91

COMMON VARIABLE IMMUNODEFICIENCY IN AN ADULT THOROUGHBRED GELDING: A COMPLEX MULTISYSTEMIC PRESENTATION	92
THE DISTRIBUTION OF INDIGENOUS DONKEY BREEDS IN CROATIA	93
STRAIGHT DISTAL SESAMOIDEAN LIGAMENT DESMITIS TREATED WITH EXTRACORPOREAL SHOCK WAVE THERAPY – A CASE REPORT	94
EXOTIC AND WILD ANIMALS SESSION	95
ORAL PRESENTATIONS	95
EVALUATION OF THE BUNNY WRAP METHOD RESTRAINT TECHNIQUE FOR CT IMAGING IN RABBITS: A ONE-YEAR EXPERIENCE.....	96
EURASIAN LYNX (<i>LYNX LYNX</i>) MORTALITY IN CROATIA IN THE 2013 – 2023 PERIOD	97
SECONDARY NUTRITIONAL HYPERPARATHYROIDISM IN A CAPTIVE CHINESE STRIPED-NECK TURTLE (<i>MAUREMYS SINENSIS</i>)- A CASE REPORT	98
FIRST INSIGHTS INTO THE MOLECULAR DIVERSITY OF <i>DIPYLIDIUM</i> AND <i>JOYEUXIELLA</i> IN CROATIA AND BOSNIA AND HERZEGOVINA.....	99
OVARIAN CYST AND FOLLICLE DEVELOPMENT IN A FEMALE PEACH-FACED LOVEBIRD (<i>AGAPORNIS ROSEICOLLIS</i>) FOLLOWING SALPINGECTOMY	100
CLINICAL APPLICATION OF PHOTOBIMODULATION THERAPY IN WILDLIFE REHABILITATION AT WILDRESCUE VEF RESCUE CENTRE	101
EXOTIC AND WILD ANIMALS SESSION	102
POSTER PRESENTATIONS	102
TUMOR OCCURRENCE IN FREE-RANGING TERRESTRIAL MAMMALS FROM CROATIA: A RETROSPECTIVE HISTOPATHOLOGIC STUDY	103
PRELIMINARY STUDY OF BLOOD FATTY ACID COMPOSITION OF FREE-RANGING GRAY WOLF FROM CROATIA.....	104
NUTRITIONAL SECONDARY HYPERPARATHYROIDISM AND SEVERE DYSTOCIA IN A VEILED CHAMELEON (<i>CHAMAELEO CALYPTRATUS</i>): A CASE REPORT	105
ANESTHETIC MANAGEMENT OF AN EURASIAN GRIFFON VULTURE (<i>GYPUS FULVUS</i>) UNDERGOING DIGIT AMPUTATION – A CASE REPORT.....	106
CASE OF COCCIDIOSIS IN THE GROUP OF GUINEA PIGS.....	107
ENDOPARASITE PROFILES IN EUROPEAN HEDGEHOGS (<i>ERINACEUS EUROPAEUS</i>) ADMITTED TO A WILDRESCUEVEF REHABILITATION CENTRE	108
INITIAL CLINICAL ASSESSMENT AND APPROPRIATE HOUSING PROTOCOLS FOR BATS IN REHABILITATION FACILITIES.....	109
WELFARE-BASED OBSERVATIONS ON CAPTIVE BREEDING OF WESTERN CAPERCAILLIE (<i>TETRAO UROGALLUS</i>) IN TWO AVIARY TYPES	110
FARM ANIMALS SESSION	111
ORAL PRESENTATIONS	111
DETECTION AND GENOMIC PROPERTIES OF UNUSUAL ROTAVIRUS A STRAINS OF ZOOONOTIC PORCINE ORIGIN IN HUMANS	112
BRAČ SHEEP AND ITS MATERNAL ORIGINS: PRELIMINARY MITOCHONDRIAL DNA FINDINGS.....	113
MELATONIN TREATMENT ENHANCES POST-THAW SPERM FUNCTION IN FRENCH ALPINE BUCKS DURING THE NON-BREEDING SEASON.....	114
TRAUMATIC RETICULOPERITONITIS IN A THREE-YEAR-OLD HOLSTEIN COW: A CASE REPORT ...	115
FARM ANIMALS SESSION	116
POSTER PRESENTATIONS	116
IMPACT OF SEX ON HOUSEKEEPING GENE STABILITY: LESSONS FROM GAPDH EXPRESSION IN THE PORCINE SMALL INTESTINE.....	117
EFFECTS OF 2.4 GHZ RADIOFREQUENCY ELECTROMAGNETIC RADIATION ON DIFFERENTIAL LEUKOCYTE COUNTS IN BROILER PARENT FLOCK	118

ENVIRONMENTAL DISTRIBUTION AND BIOLOGICAL EFFECTS OF LEAD, COPPER, AND ZINC IN HONEYBEES (<i>APIS MELLIFERA</i>) ACROSS CONTRASTING LANDSCAPES	119
DIET-RELATED ENERGETICS OF HONEYBEE LARVAE (<i>APIS MELLIFERA</i> L.)	120
VETERINARY PUBLIC HEALTH SESSION	121
ORAL PRESENTATIONS	121
EFFECTS OF THE FREEZING PROCESS ON THE PHYSICAL AND CHEMICAL PROPERTIES OF BEEF FROM DIFFERENT BREEDS AND SEXES	122
PRELIMINARY RESULTS ON THE PREVALENCE OF <i>SALMONELLA</i> SPP. SEROVARS IN CROATIA FOR 2025	123
EPIDEMIOLOGY AND SEROTYPE DIVERSITY OF <i>SALMONELLA</i> SPP. IN POULTRY AND WILDLIFE: IMPLICATIONS FOR PUBLIC HEALTH IN BOSNIA AND HERZEGOVINA	124
<i>CAMPYLOBACTER</i> OCCURRENCE IN SEABIRDS DURING THE BREEDING SEASON IN CROATIA ..	125
VETERINARY PUBLIC HEALTH SESSION	126
POSTER PRESENTATION	126
LOW-DOSE GAMMA RADIATION ALTERS PLASMA TOTAL LIPIDS IN BROILER CHICKENS EXPOSED <i>IN OVO</i>	127
THE ASSESSMENT OF <i>ANTE MORTEM</i> PROCEDURES IN THE CATTLE SLAUGHTERHOUSE RELEVANT TO ANIMAL WELFARE	128
GENERAL POSTER SESSION	129
CHEMICAL ANALYSES OF NEUROMELANIN ACCUMULATION IN ANIMAL MODELS – A REVIEW... 130	
ISCHAEMIC STROKE INDUCES REACTIVE ASTROGLIOSIS IN TRANSPLANTED NEURAL STEM CELLS	131
PROJECT SESSION	132
ORAL PRESENTATIONS	132
MIGRATION OF GABAERGIC NEURONS: INVESTIGATION OF BRAIN DEVELOPMENT IN DOWN SYNDROME	133
HUMAN CORTICO-MOTOR ASSEMBLOIDS REVEAL THE ROLE OF THE Dyrk1a GENE IN DOWN SYNDROME	134
GENES OF DOWN SYNDROME CRITICAL REGION CAUSING ABERRANT NEURONAL MORPHOLOGY	135
LIGHTING THE WAY TOWARDS IN SITU OSTEOCHONDRAL REGENERATION THROUGH MICROEXTRUSION AND FILAMENTED LIGHT BIOPRINTING (LUMINATE)	136
LIFE WILD WOLF: A LONG-TERM CONSERVATION OF WOLVES IN HUMAN DOMINATED LANDSCAPES OF EUROPE – UNDERSTANDING WOLF - DOG INTERACTIONS	137
UNIC VIP PROJECT EQUINE REPRODUCTION-EDUCATIONAL AND EXPERT COLLABORATION BETWEEN CROATIA AND BELGIUM 2026-2028	138
DEVELOPMENT OF A PROTOTYPE IMMUNOCHROMATOGRAPHIC TEST FOR THE DETECTION OF LACTOFERRIN AND CATHELICIDIN IN COW'S MILK	139
OMICS APPROACH AND DEEP PHENOTYPING IN DISCOVERING NOVEL BIOMARKERS FROM EXOSOMES IN CARDIAC DISEASES OF DOGS	140
MULTI-OMICS APPROACH IN DISCOVERING NOVEL BIOMARKERS OF EXTRACELLULAR VESICLES IN CARDIAC DISEASE OF DOGS	141
SEPSIS BIOMARKER IDENTIFICATION IN EXTRACELLULAR VESICLES OF DOGS	142
BEST PRACTICES AND INNOVATIONS FOR SUSTAINABLE BEEKEEPING (B-THENET PROJECT)	143
PROJECT SESSION	144
POSTER PRESENTATIONS	144
AVIATOR - AVIAN RESILIENCE AND ADAPTATION THROUGH AWARENESS, MONITORING, TREATMENT, AND OUTREACH FOR RAPTORS	145

INDUCTION AND PERSISTENCE OF VIABLE BUT NON-CULTURABLE (VBNC) YERSINIA ENTEROCOLITICA 4/O:3 IN PORK – PRESENTATION OF THE PROJECT	146
ADVANCING BEEKEEPING EXPERTISE THROUGH SKILLS LAB TRAINING IN VETERINARY HONEYBEE MEDICINE (EDUCATIONAL ARCHIVE STATION FOR BEEKEEPING AND B-THENET CENTAR CROATIA)	147
REACHING BEYOND BORDERS: ENHANCING COMMUNICATION AND ENGLISH PROFICIENCY IN VETERINARY MEDICINE EDUCATION - VETCOM	148
GENETIC FACTORS AND REARING STRESS AS DETERMINANTS OF QUALITY AND FUNCTIONAL INDICATORS IN BEEF MEAT – GEST BEEF	149
SUSTAINABLE MANAGEMENT OF MARINE SENTINEL SPECIES UNDER CUMULATIVE HUMAN ACTIVITIES - SAMESEA.....	150
DIGITAL PLATFORM FOR HISTOLOGY: EDUCATION, RESEARCH, AND OPEN ACCESS (VEF_HISTA+)	151
CONSERVATION MEDICINE – APEX PREDATORS AS SENTINELS OF ECOSYSTEM HEALTH	152
MULTIDISCIPLINARY DEVELOPMENT OF A SCIENTIFICALLY GROUNDED ARTIFICIAL INTELLIGENCE SOLUTION FOR RATIONAL DECISION-MAKING ON READINESS FOR DOG OWNERSHIP AND SUPPORT FOR RESPONSIBLE OWNERSHIP (PK.1.1.12.0130)	153
MOLECULAR IDENTIFICATION OF NEMATODS, TAPEWORMS, FLUKES AND OBLIGATE MYIASIS OF DOMESTIC AND WILD ANIMALS (PARKOD, NPOO).....	154
APICOMPLEXAN AND BACTERIAL TICK-BORNE PATHOGENS IN DOMESTIC RUMINANTS, HORSES AND HAEMATOPHAGOUS VECTORS (ABAVEC, HRZZ IP-2022-10-7842)	155
ROUND TABLE	156
ROUND TABLE: SOCIAL SCIENCES AND HUMANITIES IN HIGHER VETERINARY EDUCATION	157
ROUND TABLE: THE SCANDINAVIAN MODEL OR A MONOGRAPH – THAT IS THE QUESTION NOW?	158
ROUND TABLE: CHALLENGES IN VETERINARY PRACTICE TODAY	159

ABSTRACTS

KEYNOTE LECTURE

BEHIND THE STETHOSCOPE: THE HUMAN SIDE OF THE VETERINARY PROFESSION

Petra Agthe, DVM, PhD, CertVDI, Dipl. ECVDI, MRCVS EBVS® and RCVS Recognised Specialist in Veterinary Diagnostic Imaging

Southern Counties Veterinary Specialists, Hampshire, United Kingdom

Veterinary medicine is a profession grounded in scientific knowledge, technical expertise, and a strong sense of responsibility toward patients, clients, and society. Yet behind the stethoscope sits a human being, working within complex systems, under time pressure, emotional load, and often significant cognitive and moral stress. This keynote lecture explores the concept of Human Factors in veterinary practice, using lived experience with clinical error as a lens through which to examine performance, safety, and wellbeing. Human Factors is an evidence-based scientific discipline that aims to optimise how people perform within their work environments. It examines how humans interact with systems, tools, teams, and processes in order to enhance safety, efficiency, and wellbeing. Rather than focusing solely on individual competence, Human Factors shifts attention to the broader context in which work occurs and asks how conditions can be designed to support humans to perform at their best. While Human Factors have been so far mostly adopted in the aviation industry and other high-risk environments, they are also greatly relevant in veterinary medicine, where high levels of technical training coexist with a strong need for accuracy within unpredictable and often high-pressure environments. Clinical errors rarely arise from a lack of knowledge alone. More commonly, they occur when well-trained professionals are placed in conditions that make it difficult to consistently apply that knowledge.

Drawing on personal experiences of clinical error, this lecture highlights how Human Factors offer a constructive framework for understanding why things go wrong and how we can learn from them. Errors are explored not as individual failures, but as signals of system vulnerabilities and suboptimal fit between the environment on one hand and the capabilities and limitations of human beings on the other. The lecture introduces some key components of Human Factors and their relevance to veterinary practice. These can be grouped into several interdependent categories, including:

Systems and Processes form the foundation of how work is structured. Protocols, workflows, checklists, physical layouts, and digital systems all influence how easily tasks can be performed and how likely errors are to occur. While this lecture touches on these elements briefly, the primary focus remains on the human experience within these systems.

Skills and Knowledge, particularly non-technical skills, play a critical role in safe and effective practice. These include situational awareness, decision-making, communication, teamwork, leadership, and the ability to manage uncertainty. Non-technical skills shape how clinicians respond to complexity, collaborate with colleagues, and navigate challenging interactions with clients and team members.

Health and Wellbeing are central to Human Factors. Fatigue, stress, moral distress, and burnout directly impair cognitive performance, attention, and judgement. Recognising the impact of physical and psychological health on clinical work is not a personal weakness, but a

professional responsibility. Supporting wellbeing and ergonomical considerations are therefore an essential component of patient safety.

Culture encompasses the shared values, attitudes, and behaviours within teams and organisations. Culture influences how mistakes are perceived, whether learning is prioritised over blame, and whether people feel psychologically safe to speak up. A strong, positive culture enables both high performance and compassionate care, while a punitive or silence-driven culture ultimately increases risk.

This keynote invites a reframing of how the veterinary profession understands error, performance, and professionalism. By acknowledging the human side of veterinary work and applying Human Factors principles, we can create safer systems, healthier teams, and more sustainable careers — not despite our humanity, but because of it.

INVITED LECTURES

FIP – DIAGNOSTIC POSSIBILITY IN THE INHOUSE LABORATORY

Erika Furman, DVM, Dipl. ECVCP, FTA

www.e-fur.com, Hollabrunn, Austria

InHouse laboratories are defined as laboratories placed in veterinary organisations/facilities. This definition is set by the author for purpose of this lecture. These labs are used for routine measurements of diverse patients' fluid and nonfluid material. The goal is to achieve fast reliable results that enable quick therapeutic or diagnostic response, which is highly preferable in any veterinary organisation.

Regulations, recommendations, requirements of such InHouse laboratories lacking, so the veterinarian in charge for the laboratory service is forced to postulate a quality assessment plan to ensure adequate performance, quality and production of reliable results.

Veterinary clinical pathology (Vet Clin Path, VCP) is a speciality that include the field of laboratory management. Specialist of Vet Clin Path are trained, among others, how to correctly perform and monitor laboratory quality, quality assessment, quality control, analyzer performance, method validation etc. on the field haematology, biochemistry, hormones, cytology and can be of great help establishing a desired quality assessment plan for an InHouse Lab.¹

In a quality InHouse laboratory reliable quality results can be produced which is desired from all aspects of diagnostic processes, not only FIP-diagnostics.

Feline infectious peritonitis (FIP) is a worldwide disease of domestic and wild felids. The pathogen of FIP is feline infectious peritonitis virus (FIPV), which is mutated from feline coronavirus (FCoV). FIP has high mortality rate and was in the past considered as a terminal disease. Gold standard for FIP diagnosis is immunohistochemistry (IHC) to identify FCoV antigens in diseased tissues. Clinical signs are not very specific form anorexia, ADR (a`int doing right), fever and weight loss. Environmental facts can add significantly to the disease process/occurrence. FIP can be mainly divided into three types effusive, non-effusive and mixed. Effusive FIP is mainly manifested as ascites and/or pleural effusion, while non-effusive FIP is mainly manifested as granuloma formation involving the central nervous system, eyes and abdominal organs. When effusive and non-effusive signs occur together, it is mixed FIP.²

According to some studies, the latest terminology for the FECV (felines enteral Coronavirus, FCoV), is using the new term "low virulent FCoV" and formerly FIPV (felines infectious Peritonitis Virus) using the new term „FIP-associated FCoV“ that can efficiently replicate in feline monocytes and macrophages.³

In House laboratory can determine Minimal Lab Data Base (MLDB) results. It is strongly advised to set up a quality assessment plan and to monitor, that the lab personal is adequately trained. MLDB include:

- Complete blood count with a blood smear evaluation
- Biochemistry profile that includes Tbil, TP, Alb, calculate A/G ratio
- Complete Urinalysis.

In case a body cavity effusion can be found in a patient the effusion evaluation is essential and crucial to clarify disease processes that can cause a body cavity effusion. In many cases it can increase the suspicion of a possible FIP infection.

Basic Effusion Evaluation:

- Macroscopic description
- Total nucleated cell count (TNCC)
- Total Protein
- Cytology (FIP susp: low TNCC, high TP, → typical proteinaceous granular background, mixture of macrophages, neutrophils, few lymphocytes and eosinophils. No infectious agents or neoplastic cells)

If FIP suspected: add measurement of albumin to calculate A/G ratio from the effusion. If low, is moderately likely having FIP.

In cases, where is not clear having a protein rich transudate or exudate, determination of LDH activity with wet chemistry is of benefit.⁴

Determination of acute phase protein as SAA and AGP is helpful.⁵ There are some POC devices for InHouse SAA testing available with diverse performance. SAA is not highly specific, but a low SAA makes FIP not highly likely.

AGP can be determine only in professional laboratories.

In case no effusion is noted but FIP is suspected, sampling of fund masses is warranted. The cytological evaluation can give crucial answers about the nature of such lesions as inflammation, type of inflammation, neoplasia yes/no or both. Stained and unstained cytological slides can be used for genetic testing as PCR.

Genetic testing

From effusions, FNAs from masses, cytology slides etc can be used for genetic testing. The infectious agent FIPV can be determined via rt-PCR⁵ (contact your PCR lab for details).

Antibody testing is not highly sensitive nor specific not in effusion not in peripheral blood.

Some rapid antigen lateral flow immunochromatographic assay for the qualitative detection of FIPV antigens in feline faeces or ascites are available (detailed information not known to the author).

One promising InHouse fast PCR method was developed and compared to the conventional FCoV RT-qPCR genetic test with high specificity; was recently published.⁶

Summary

Looking overall, FIP diagnostics is a multifactorial process, that includes many different aspects from the veterinary diagnostic field. It can be seen as a mosaic- creation where some stones are larger and some are smaller. However, only if majority of them are in place, a whole picture/FIP diagnosis can be revealed.

Laboratory results of diverse analytes are important in the FIP diagnostic steps, with diverse sensitivity, specificity and diagnostic accuracy. Many of these results can be produced in an InHouse lab, preferable with a quality assessment program.

Currently there is no single test, that can either 100% diagnose or 100% exclude a FIP infection.

References:

1. Flatland et al. ASVCP guidelines: quality assurance for point-of-care testing in veterinary medicine. *Vet Clin Pathol*, 2013.
2. YiyaYin et al. A retrospective study of clinical and laboratory features and treatment on cats highly suspected of feline infectious peritonitis in Wuhan, China. *Scientific Reports*, 2021.
3. Katharina Zwicklbauer et al. Feline infectious peritonitis – a current overview. *Tierarztl Prax Ausg K Kleintiere Heimtiere*, 2025.
4. Smuts et al. Transudate or exudate: can lactate dehydrogenase activity in canine and feline effusions help to differentiate between the 2? *Vet Clin Path*, 2016.
5. Thyer et al. 2022 AAFP/EveryCat Feline Infectious Peritonitis Diagnosis Guidelines. *Journal of Feline Medicine and Surgery*, 2022.
6. Doki T et al. Development of rapid and simple FCoV RNA detection systems using RT-PCR and RT-RPA combined with STH-PAS to diagnose FIP in cats. *J Virol Methods*, 2025.

NEUROLOGIC FORM OF FELINE INFECTIOUS PERITONITIS – A BRAIN TEASER

Filip Kajin, DVM, PhD, Dipl. ECVN

Clinic for Internal Diseases, Faculty of Veterinary Medicine, University of Zagreb, Zagreb, Croatia

Feline infectious peritonitis (FIP) is a historically fatal, inflammatory disease caused by infection with feline coronavirus (FCoV). While FCoV infection is common and typically results in mild or subclinical enteric disease, a minority of cats develop FIP following viral mutation and the emergence of a macrophage-tropic biotype. The ensuing dysregulated immune response leads to a systemic vasculitis and pyogranulomatous inflammation. FIP classically presents in effusive (“wet”) and non-effusive (“dry”) forms; however, neurological involvement represents a distinct and clinically significant manifestation that may occur alone or in combination with other systemic signs.

The disease is over-represented in young cats, yet clinicians should remain alert across age groups, particularly in multicat environments or where systemic inflammatory signs accompany neurologic disease. The pathogenesis reflects viral replication within monocytes/macrophages and immune-mediated inflammation targeting the central nervous system (CNS), particularly the meninges, choroid plexus, and periventricular regions. Lesions typically manifest as pyogranulomatous meningoencephalitis and ependymitis, often with secondary obstructive or communicating hydrocephalus. Spinal cord involvement may also occur, and is usually located in the cervical spine.

Clinical presentation is often multifocal and progressive. Common signs include altered mentation, ataxia, central vestibular dysfunction, epileptic seizures, behavioural changes, and cranial nerve deficits (e.g., anisocoria, reduced menace response). Spinal pain or paresis may be observed in cases with spinal cord involvement. Ocular abnormalities such as anterior uveitis or chorioretinitis frequently coexist and can provide an important diagnostic clue. Systemic findings (e.g., weight loss, fever, lethargy) may be mild or absent in exclusively neurologic cases, complicating recognition in general practice.

Diagnosis of neurologic FIP is challenging and typically relies on integration of signalment, clinical findings, laboratory data, and advanced diagnostics. Routine haematology and biochemistry may reveal nonspecific changes such as hyperglobulinaemia or decreased albumin-to-globulin ratio. Magnetic resonance imaging commonly demonstrates ventricular dilation, meningeal contrast enhancement, and periventricular lesions. Cerebrospinal fluid (CSF) analysis frequently reveals a marked neutrophilic or mixed pleocytosis with elevated protein concentration. Detection of FCoV RNA in CSF by polymerase chain reaction (PCR) can support the diagnosis when interpreted alongside compatible clinical and laboratory findings; however, no single test is definitive in all cases. Histopathology with immunohistochemistry remains the gold standard but is rarely pursued ante-mortem.

Neurologic FIP should be considered in young cats with progressive multifocal CNS disease, particularly when systemic inflammatory indicators and inflammatory CSF changes are present. Early recognition and appropriate diagnostic investigation are essential for accurate case management and client communication.

FIP FROM CHALLENGE TO CURE – CURRENT TREATMENT OPTIONS, THERAPY MONITORING AND POTENTIAL SIDE EFFECTS

Katarina Buchta, DVM

Laboklin GmBH & CO KG, Laboratory for clinical diagnostics, Bad Kissingen, Germany

Feline infectious peritonitis (FIP), caused by feline coronavirus (FCoV), was long considered fatal with a median survival time of nine days. Therapeutic options have evolved substantially over the past years. Initial management relied on unsuccessful therapies such as glucocorticoids or interferons. Better outcomes were later reported with protease-inhibitors, e. g. GC-376 while nucleoside analogues led to the breakthrough. For now, the most promising antiviral drug is GS-441524 (and its prodrug remdesivir) while molnupiravir has recently gained clinical relevance as an alternative option. The currently recommended treatment protocol is GS-441524 in a dosage of 15 mg/kg once daily orally for 42 days. Some authors recommend higher daily doses of 20 mg/kg (divided into two administrations per day) for cats with neurological or ocular involvement. During antiviral treatment some mild to moderate side effects have been observed, e.g. diarrhea, lymphocytosis or eosinophilia as well as an increase in kidney function parameters or liver enzyme activity. Also, the formation of uroliths has been described in two cats during antiviral treatment. These cats received a high dosage of illegally produced GS-441524 over an extended treatment period.

In a prospective controlled study, the efficacy of an 84-days-treatment was compared with a shorter treatment duration of 42 days. No clinically relevant statistically significant differences were observed between the treatment groups, with the exception of lymphocyte and eosinophil counts. Cats treated for 84 days showed significantly higher lymphocyte and eosinophil counts compared with cats receiving treatment for only 42 days. The recommended dosage of molnupiravir is 10–20 mg/kg twice daily orally. However, due to its mutagenic and teratogenic effects, it is associated with more severe side effects than GS-441524, e.g. severe cytopenia, broken whiskers or folded ears and is therefore recommended as a second-line therapeutic option.

With the availability of effective antiviral treatment for FIP, research also focuses on less commonly described clinical manifestations of FIP, e.g. myocarditis or immune-mediated hemolytic anemia (IMHA). In cats with suspected myocarditis, measurement of cardiac troponin I (cTnI) can be helpful for the assessment of myocardial damage. In cases of increased cTnI levels a detailed cardiologic examination should be performed to determine whether additional symptomatic treatment is required.

FIP can be a cause of associative IMHA and should be considered if hematocrit levels fail to improve during antiviral treatment in cats with FIP. Additional treatment such as systemic glucocorticoids or blood transfusion might be necessary. In many cats, additional symptomatic treatment is essential to support recovery and must be tailored to individual needs. Antiemetics or prokinetics, appetite stimulants, fluid therapy and other supportive medications might be necessary. Food intake is crucial in these cats, as many have experienced significant weight loss

due to FIP. If symptomatic treatment is insufficient to ensure adequate food intake, these cats might benefit from the placement of a feeding tube.

Currently, a treatment duration of 42 days with legally sourced oral GS-441524 is recommended. The monitoring during treatment is essential for optimal outcomes. An improvement in behavior and appetite should be noted in the first days/first week after treatment initiation. Cats should gain appetite and consequently also weight (a temporary decline in body weight may occur in the first days due to reduction/resorption of effusions) and should return to their normal, familiar behavior. Check-ups are recommended on days 7, 28 and 42 after treatment initiation, when the initial clinical response is adequate. In cats with persistent clinical signs and/or large amount of effusion on day 7, or in those with comorbidities or complications, an additional check up on day 14 should be performed. By day 7, SAA levels have often returned to the reference interval. Over the subsequent weeks, further clinical improvement, reduction of effusion and normalization of laboratory parameters are expected. By day 28 (two weeks prior to the planned end of treatment), there should be no abnormalities in the clinical examination and blood assessments related to FIP. In these cases, antiviral treatment can be stopped on day 42. In the first 6 weeks after stopping the treatment a close monitoring for clinical signs (such as appetite or weight loss) of relapse is recommended.

Alpha-1-acid-glycoprotein (AGP) plays an important role in monitoring cats during and after treatment. Normalization of AGP levels should be observed by day 28 of treatment and a study demonstrated that AGP can be used to differentiate between remission and recovery. Fully recovered cats had normal AGP concentrations on day 28 unlike cats, which were merely in remission. With AGP concentrations still (slightly) elevated on day 28 relapse occurred more often. Therefore, AGP might be a marker for assessing relapse in these cats.

In conclusion FIP can present with various (less known) clinical manifestations and effective antiviral treatment options are available. The recommended treatment protocol is 15 mg/kg once daily orally with GS-441524 for 42 days. However, intensive monitoring during and after treatment is essential to ensure a favorable outcome and AGP plays an important role in monitoring cats during and after treatment.

BEYOND INSULIN: SGLT2 INHIBITORS IN FELINE DIABETES MELLITUS

Elizabetha Pongrac, DVM

Clinic for Internal Diseases, Faculty of Veterinary Medicine, University of Zagreb, Zagreb, Croatia

Feline diabetes mellitus (DM) is most commonly analogous to type 2 diabetes in humans, characterized by insulin resistance and variable preservation of endogenous insulin secretion. Traditional management has relied primarily on insulin therapy combined with dietary modification. However, novel therapeutic approaches targeting renal glucose handling are expanding available treatment options.

This presentation reviews the role of sodium–glucose co-transporter 2 (SGLT2) inhibitors in feline diabetes management, with emphasis on velagliflozin as a once-daily oral treatment alternative. SGLT2 inhibitors act at the level of the renal proximal tubule by blocking glucose reabsorption, thereby promoting glucosuria and reducing hyperglycaemia independently of insulin action. This mechanism alleviates glucotoxicity and may support improved β -cell function.

Appropriate case selection is essential. SGLT2 inhibitors are indicated only in clinically stable, non-ketotic diabetic cats with sufficient endogenous insulin production and should not be combined with insulin therapy. Careful monitoring is required, particularly during the first two weeks of treatment, due to the risk of diabetic ketoacidosis (DKA) and euglycaemic DKA.

Therapeutic goals in feline DM remain individualized and include achieving optimal body condition score, resolving clinical signs, and minimizing the risk of hypoglycaemia. When used in properly selected patients, SGLT2 inhibitors represent an effective, practical, and less invasive alternative to injectable insulin therapy.

HOW SERIOUS IS THE PROBLEM OF MDR1 GENE DEFECT IN EVERYDAY PRACTICE?

Davorin Lukman¹, DVM, PhD; Doris Breu, PhD²

¹ LABOKLIN – SE Europe Manager

² LABOKLIN GmbH & Co. KG – Klinische Labordiagnostik

In 1981, a broad spectrum anti-parasitic Ivermectin was synthesized. In 1983, first reports of neurological outbreaks in Collies treated with Ivermectin were recorded, and later in Bobtail dog breed and their crossbreeds. Therefore, there was strict prohibition of its usage in further prescriptions for these two breeds as well as their crossbreeds. By testing mice in 1990, it was established that medicine concentration in mice with a defect in blood-brain barrier was 80-90 times higher than allowed. It has been proven that this is a genetically determined lack of MULTI DRUG RESISTANCE TRANSPORTER (P-glycoprotein), whose physiological role is to act as a transport pump in brain cell membranes preventing entry of undesirable substances into brain tissue. Medication Ivermectin is completely safe to use in healthy dogs, even at maximum doses of 2000 mcg/kg. However, toxic dose for a dog with MDR1 gene defect is already 150mcg/kg! Breeds in which possible defect has been discovered so far are: Bobtail, Collie, Border Collie, Australian Shepherd, German Shepherd, White Swiss Shepherd, Longhaired Whippet, Elo, McNab, Sheltie, Silken Windhound and Waeller. Consequence of this defect is that active substance enters the brain directly, which will be clinically manifested by neurological disorders, walking problems, incoordination, disorientation, vomiting, tremor, dilated pupils, coma and death.

Genetic tests carried out so far prove that in mentioned dog breeds 69% of dogs are free of MDR1 gene defect, 26% are carriers of defect and 5 % will have a clinical picture of intoxication after using medications from the list:

CLASS A – DO NOT use in dogs with MDR1 Gene Defect!

- **Ivermectin** (Diapec[®], Ecomectin[®], Equimax[®], Eqvalan[®], Ivomec[®], Noromectin[®], Paramectin[®], Qualimec[®], Sumex[®], Virbamec[®])
- **Doramectin** (Dectomax[®])
- **Moxidectin** (Cydectin[®], Equest[®])
- **Loperamid** (Imodium[®])

CLASS B – *reaction* occurs only with some active substances; use only in the presence and under supervision of a veterinarian

- **Cytostatics:** Actinomycin D, Daunorubicin, Docetxol, Doxorubicin, Etoposid, Imatinib, Irinotecan, Mitomycin C, Mitoxantron, Paclitaxel, Teniposid, Topotecan, Vinblastin, Vincristin
- **Immunosuppressives:** Cyclosporin A, Sirolimus, Tacrolimus, Valspodar
- **Cardiac glycosides:** Celiprolol, Digoxin, Diltiazem, Losartan, Methyl digoxin, Talinolol, Quinidin, Verapamil
- **Opioids:** Fentanyl, L-Methadon, Morphin, Butorphanol
- **Antiemetics:** Ondansetron, Domperidon

- **Antibiotics:** Erythromycin, Grepafloxacin, Levofloxacin, Rifampicin, Sparfloxacin, Tetracyclines
- **Antifungals:** Itraconazol, Ketoconazol
- **Antivirals:** Amprenavir, Indinavir, Nelfinavir, Ritonavir, Saquinavir
- **Antiparasitics:** Milbemycinoxim, Selamectin, Emodepsid (Profender®), Spinosad (Comfortis®)
- **Antiepileptics:** Phenobarbital, Phenytoin
- **Antacids:** Cimetidin, Ranitidin
- **Antiallergics** (npr. Ebastin®)
- **Glucocorticoids:** Aldosteron, Corisol, Dexamethason, Methylprednisolon
- **OTHERS:** Acepromazin, Atorvastatin, Colchicin, Fexofenadin, Terfenadin, Vecuronium

CLASS C – products can be used under strict supervision in the form and dosage prescribed by the manufacturer

- Stronghold® (Selamectine), Advocate® (Moxidectine), Milbemax®, Program Plus® (Milbemycinoxime), Bravecto® (Fluralaner)

Veterinarian's primary task is to make the owners of above-mentioned breeds aware of the problem in question and suggest to test their pets before using any of the listed medications. Otherwise, their usage could be fatal to their pets. Next task is to eliminate the genetic defect carrier from breeding. Also, it should be noted that the gene is inherited in a recessive way, but depending on the dose of an administered product, even defect carriers (genotype N/MDR) may have symptoms of intolerance. Sample to be sent is EDTA blood or buccal swab. Turnaround time is 7-14 days.

BUILDING A VETERINARY PRACTICE THAT WORKS. IDEA STRATEGY. TEAM. CLIENT CARE.

Veljko Turković, DVM

Fachtierarztpraxis für Kleintiere -Tierarztpraxis Bahnstraße, Wolkersdorf, Austria

The critical role of leadership and teamwork is essential for achieving sustainable success in veterinary practices. Drawing on over fifteen years of experience across clinical, academic, and entrepreneurial roles in Europe, the speaker offers a practical, research-informed perspective relevant to both academic institutions and private clinics.

The concept of the inverted pyramid of leadership is introduced, where leaders support and empower their teams from the base rather than leading from the top down. This model underscores the importance of veterinary support staff—including technicians and nurses—and promotes interdisciplinary collaboration as key to delivering high-quality care.

Focus should shift from solely investing in new equipment to prioritising education, workplace culture, and professional development, which have a deeper and more lasting impact on practice outcomes. It is also highlighted that the need to address existing challenges—such as poor leadership and weak team dynamics—should come before introducing organisational change. Investing in regular team training sessions and leadership workshops reported not only smoother daily operations but also higher staff retention rates and better client feedback.

Finally, the value of collaboration between general practices and referral networks is identified as a cornerstone for clinical excellence and long-term professional resilience.

The message is clear: by prioritising people, building trust, and empowering teams, veterinary professionals—whether in academia or private practice—can foster sustainable growth, enhance well-being, and contribute to elevating the profession as a whole.

EQUINE WOUND MANAGEMENT

Assoc. Prof. Nika Brkljača Bottegaro, DVM, PhD, Dipl. ECVSMR

Clinic for Surgery, Orthopaedics and Ophthalmology, Faculty of Veterinary Medicine, University of Zagreb, Zagreb, Croatia

Wound management is one of the most frequent interventions in equine practice, playing a critical role in maintaining equine health, athletic performance, and welfare by supporting the natural healing process and reducing the risk of complications. A comprehensive understanding of wound healing principles is essential for selecting appropriate treatment strategies, improving clinical outcomes, and minimizing morbidity. Wounds are classified by type: closed (crush injuries, contusions) or open (abrasions, avulsions, incisions, lacerations, punctures) and by contamination status, as clean or contaminated.

When tissue integrity is disrupted, wound healing begins as a highly coordinated process involving three partially overlapping phases: the inflammatory phase, the proliferative phase (characterized by tissue formation), and the maturation phase (remodeling). The approach to wound closure depends on multiple factors, including wound type, anatomical location, degree of contamination, and stage of healing. Full-thickness wounds may be managed through primary closure, delayed primary closure, secondary closure, or by allowing healing by second intention.

In horses, wounds of the distal limb, areas characterized by high tension and motion, occur frequently due to their natural behavior and environment. These wounds exhibit delayed healing compared to similar-sized wounds on the upper body. The delay is primarily attributed to a lower rate of epithelialization and contraction due to excessive motion, increased risk of infection, and the development of exuberant granulation tissue (EGT). An additional complication in distal limb wounds is exposed bone, which, when deprived of periosteum, can desiccate and lead to sequestrum formation. Furthermore, wound dehiscence is commonly associated with infection, often resulting from primary contamination of traumatic wounds and environmental factors.

Exuberant granulation tissue is both a cause and a consequence of delayed healing in wounds healing by second intention. It results from a prolonged inflammatory phase that drives an excessive proliferative response, with impaired fibroblast differentiation into myofibroblasts. This leads to wound expansion, delayed contraction, and inhibited epithelialization. In distal limb wounds, microvascular occlusion and hypoxia further stimulate angiogenic and profibroblastic activity, promoting EGT formation. Management focuses on minimizing inflammation once healthy granulation tissue forms and excising EGT when it protrudes beyond wound margins. The use of non-adherent silicone dressings is recommended to reduce recurrence.

Biofilm is a structured community of bacteria that creates a protective environment, making microorganisms tolerant to antibiotics and resistant to host immune responses. In equine wounds, particularly those on distal limbs healing by second intention, biofilm formation is a significant factor contributing to delayed healing. Given the limited effectiveness of systemic antibiotics in the presence of biofilm, the recommended approach involves periodic wound debridement to physically disrupt and remove the biofilm, combined with appropriate topical therapy.

Initial wound management begins with thorough assessment in a safe environment, including physical examination, analgesia, and blood work. Proper clipping and preparation precede debridement and treatment planning. Primary closure is suitable for wounds with minimal tissue loss and contamination, delayed primary closure is indicated for mild contamination, while second-intention healing is reserved for gross contamination or tissue loss. Dressing selection plays a critical role and should be tailored to the wound's healing stage. Understanding these challenges and implementing evidence-based strategies are key to improving outcomes in equine distal limb wound management.

In wound closure, it is essential to select a suture type and size that matches the strength of the tissue. Suture placement should minimize tension at the skin edges while preserving adequate blood supply. A wide range of topical wound treatments is available, however, not all are beneficial. Careful selection based on a thorough understanding of wound physiology is critical for successful healing. Nonsteroidal anti-inflammatory drugs can suppress the inflammatory response, but their use must be balanced against the need for effective analgesia and the prevention of excessive tissue swelling, which itself can negatively impact the healing process.

The BEVA Primary Care Clinical Guidelines on Wound Management (2021) emphasize the importance of evidence-based therapeutic protocols. However, high-quality studies in horses remain limited, and many recommendations are extrapolated from human medicine. Significant gaps in equine-specific research persist across several aspects of wound care.

Our interventions can directly influence the dynamic process of wound healing. To optimize outcomes, it is essential to understand the underlying physiology and select treatment options based on the best available evidence.

TETANUS IN HORSES: WHEN A WOUND BECOMES A DANGER AND PREVENTION IS THE KEY

Assist. Prof. Matko Perharić, DVM, PhD

Department for Microbiology and Infectious Diseases with Clinic, Faculty of Veterinary Medicine, University of Zagreb, Zagreb, Croatia

Tetanus is a frequently fatal neurological disease caused by the potent neurotoxin tetanospasmin, produced by *Clostridium tetani*, a Gram-positive, spore-forming obligate anaerobic bacterium widely distributed in the environment. Infection usually occurs after wounds are contaminated with bacterial spores, which germinate under anaerobic conditions in necrotic or infected tissue. The incubation period is about 7 days but can range from 3 to 21 days. Horses are considered the most susceptible domestic species. Typical clinical signs include hyperaesthesia, trismus, prolapse of the third eyelid, dysphagia, dyspnoea, and lateral recumbency. Reported mortality rates in equine tetanus range from approximately 23% to 75%. Despite the availability of effective vaccines, tetanus remains a significant threat to equine health due to incomplete vaccination. As treatment efficacy is limited once clinical signs develop, prevention through vaccination programmes is essential.

Immunological protection against tetanus is primarily achieved through circulating antibodies that neutralise the tetanospasmin toxin. Vaccination with tetanus toxoid induces a strong humoral immune response and establishes lasting immunological memory. In contrast, infection with *Clostridium tetani* does not consistently result in protective immunity, as the amount of toxin required to cause clinical disease is insufficient to provoke an effective immune response. Therefore, horses that survive tetanus remain susceptible to reinfection and require vaccination to achieve adequate protection. Evidence from experimental challenge models and serological studies indicates that tetanus toxoid immunisation provides robust and long-lasting protection in horses, even when antibody concentrations decline over time, highlighting the persistence of immunological memory.

Current vaccination guidelines and manufactures instructions recommend to start vaccination in foals between 5 to 6 months of age, followed by second administration of vaccine after 4 to 6 week and third dose at the age of 10 months (5 month after initial vaccination). In cases of increased risk or insufficient colostrum intake, an additional dose of vaccine may be given at 4 months of age, followed by a complete vaccination programme (first vaccination at 5–6 months of age and revaccination 4–6 weeks later). In foals under three months old, protection relies primarily on passive immunity acquired through colostrum. Therefore, ensuring adequate maternal immunisation is essential for neonatal tetanus prevention.

Vaccination of broodmares plays a crucial role in controlling tetanus in their offspring. Because the equine placenta type prevents significant transplacental immunoglobulin transfer, administering a tetanus toxoid booster four to eight weeks prior to parturition significantly increases colostrum antibody concentrations and ensures effective passive transfer of immunity to the foal. When adequate passive transfer is achieved, foals are generally protected against

tetanus for up to six months of age. In contrast, foals born to unvaccinated mares are at a substantially increased risk of tetanus.

Following completion of the primary vaccination protocol, booster immunisation is essential to maintain long-term protection. Although some studies indicate multi-year immune protection after a properly implemented primary vaccination protocol, most vaccine manufacturers recommend booster doses at intervals of no more than two years. Accurate record-keeping and adherence to defined booster schedules are therefore fundamental elements of effective tetanus prevention programmes.

In addition to routine vaccination, managing tetanus risk events is a critical aspect of preventive care. Horses often encounter unpredictable situations that create anaerobic tissue environments favourable for *Clostridium tetani* proliferation, such as wounds, hoof abscesses, surgical procedures, umbilical infections in foals, and periparturient trauma. In horses with a documented and current vaccination history, pre-existing immunity is generally sufficient to prevent disease after such events. However, in unvaccinated horses, those with unknown vaccination status, or foals born to unvaccinated mares, combined active and passive immunisation is recommended. This involves simultaneous administration of tetanus toxoid and tetanus antitoxin at separate injection sites, followed by completion of the appropriate primary vaccination course.

Despite improvements in intensive care and supportive treatment, tetanus remains associated with high morbidity, prolonged recovery, and significant welfare concerns. In contrast, vaccination against tetanus is safe, cost-effective, and highly protective. From both clinical and welfare perspectives, prevention through vaccination far outweighs reliance on therapeutic intervention.

REPRODUCTIVE SYSTEM INJURIES IN HORSES

Juraj Šavorić, DVM, PhD

Clinic of Obstetrics and Reproduction, Faculty of Veterinary Medicine, University of Zagreb, Zagreb, Croatia

Damage to the reproductive system of horses is a clinically important issue that can negatively influence fertility, performance, and general health. Such injuries may affect both the external and internal reproductive organs and are observed in mares as well as stallions. They arise from a wide range of causes, including trauma during mating, accidents, difficult parturition, post-surgical complications, infectious processes, and behavioral aggression. In mares, lesions most commonly involve the vagina, cervix, uterus, and ovaries, whereas in stallions the penis, prepuce, testes, and surrounding structures are more frequently affected. The severity of clinical signs depends on the extent and location of the injury and may range from localized swelling and discomfort to severe hemorrhage, reproductive failure, or conditions that threaten the animal's life. Diagnosis is based on careful clinical evaluation supported by imaging techniques such as ultrasonography and endoscopy, along with relevant laboratory tests. Management strategies vary according to the type of injury and may include conservative medical treatment, surgical correction, or long-term supportive care. Timely intervention is essential to reduce complications and improve the chances of maintaining reproductive function. Preventive practices, including controlled breeding, appropriate housing, and proper handling, are key factors in lowering the risk of reproductive system injuries. This lecture reviews the main forms, causes, diagnostic approaches, and treatment options related to reproductive injuries in horses, highlighting their relevance in equine veterinary medicine.

CLIENT COMMUNICATION: HOW TO CONDUCT DIFFICULT CONVERSATIONS

Andrea Ražić Pavičić, DM

Department of Psychosomatics and Psychotherapy, Clinic for Psychiatry and Psychological Medicine, Zagreb, Croatia

Difficult conversations are an integral and inevitable part of veterinary clinical practice. Unlike human medicine, veterinary communication occurs within a triadic relationship between the veterinarian, the client, and the animal, encompassing medical, emotional, ethical, and financial dimensions of decision-making. In this context, communication is not merely the transmission of information; it is a process of regulating emotions, clarifying values, and making structured decisions under conditions of uncertainty.

From a psychological perspective, difficult conversations arise in situations of emotional activation and value conflict. Clients face potential loss, guilt, and a perceived loss of control, which can reduce their cognitive capacity to process information. In such circumstances, rational explanations of medical facts are often insufficient. Emotional validation becomes a prerequisite for constructive communication and informed decision-making.

At the same time, the veterinarian occupies the role of both advisor and moral agent—a professional responsible for safeguarding the animal's welfare and establishing ethical boundaries, especially when disagreements with the client arise. These situations often require decisions between competing values, such as extending life versus quality of life, medical ideal versus financial constraints, or differing interpretations of suffering. It is precisely in these moments that communication becomes a key clinical intervention.

This work presents a structured model for conducting difficult conversations in veterinary practice, grounded in contemporary insights from emotional regulation, cognitive load theory, and shared decision-making frameworks. The model includes several key steps:

1. Veterinarian self-regulation before and during the conversation.
2. Explicit validation of the client's emotions.
3. Exploration of the values underlying the decision.
4. Clear and structured presentation of medical options and their consequences.
5. Linking options to the client's priorities to enable informed and value-congruent decision-making.

The emphasis is on understanding that difficult conversations are not a communication failure but a structural feature of the veterinary profession. Well-conducted conversations can reduce conflict, increase client satisfaction, decrease veterinarians' moral stress, and contribute to better animal care. Given the high emotional involvement inherent in veterinary practice, developing communication skills that integrate medical expertise with psychological competence is an essential component of professional sustainability and the well-being of the entire veterinary team.

FROM ZOO TO THE WILD – VETERINARY EXPERIENCE WITH WILD CARNIVORES

Pavel Kvapil, DVM, PhD, Dipl. ECZM (ZHM)

Ljubljana ZOO, Ljubljana, Slovenia

Veterinarians working in zoological institutions face a wide range of animal species, often with intriguing anatomical and physiological characteristics that pose daily clinical challenges. Large carnivores such as lions, tigers, and leopards present specific difficulties related to their size, strength, and limited accessibility, particularly during anaesthesia induction and recovery.

The Ljubljana Zoo veterinary team performs between 50 and 80 planned or emergency anaesthetic procedures in large animals annually, approximately 20% of which involve carnivores. In addition, close cooperation with field biologists includes projects involving free-ranging lynx and wolf populations. These activities cover anaesthesia, peri-anaesthetic monitoring, clinical health assessment, and sampling for paraclinical diagnostics in approximately 30 lynxes and 12 wolves in last 7 years. Lynxes were captured using three different methods: walk-in box traps, spring snares, and a remote drug delivery dart system (Gameboy). Each method imposes different stress levels and logistical challenges, often under harsh field conditions, including low temperatures and remote locations. During anaesthesia in field conditions, precise clinical monitoring, oxygen supplementation, temperate fluids application as well as i.v. line access and oxygen saturation monitoring are mandatory.

Veterinarian working with biologists in conservation field projects ensured thorough clinical evaluation, which led to the detection of heart murmurs in individuals from the fragmented and inbred Dinaric lynx population (*Lynx lynx*). These murmurs were associated with atrial septal defects, later confirmed by field doppler ultrasonography.

Collaboration between veterinarians and biologists in conservation projects involving free-ranging carnivores is mutually beneficial. Such cooperation significantly improves anaesthetic safety, recovery quality, and successful post-anaesthetic reintroduction of wild carnivores into their natural environment.

Keywords: wildlife anaesthesia, zoo veterinarian, field monitoring, lynx, conservation medicine

ANAESTHESIA AND SURGERY IN AFRICAN PYGMY HEDGEHOCKS

Assoc. Prof. Joško Račnik, DVM, PhD, Dipl. ECZM (Wildlife Population Health)

Clinic for Birds, Small Mammals and Reptiles, Veterinary faculty, University of Ljubljana, Ljubljana, Slovenia

As in other animals, in African pygmy hedgehogs preoperative clinical examination with blood work and biochemistry testing is important. Also, abdominal ultrasonography is very useful in surgical planning. A several hours fasting is recommended before anaesthesia and proper thermal support is provided for the hedgehog before, during, and after surgery and is essential for a successful outcome of the surgical procedure. Before surgery, the patient is given analgesia, fluids, and other medications according to different protocols. After premedication the patient is preoxygenated, and isoflurane alone is used for the induction and maintenance of anaesthesia. A large aesthetic mask or induction chamber is usually used. Tracheal intubation is recommended for longer and oral procedures with 1.0 to 2.0. mm tubes, yet intubation is challenging due to small size of oropharynx. Useful anaesthetic monitoring tools in hedgehogs includes Doppler, pulse oximetry, electrocardiography, capnography and rectal body temperature monitoring. During abdominal surgery, African pygmy hedgehogs are positioned similarly to other mammals. The largest possible incision should be prepared for, and standard patient surgical preparation is undertaken with drapes from various materials. In some cases, magnification is a very useful tool, and head-mounted focal light sources are very important for illuminating deep into the abdominal cavity. The Lone Star™ or other small retractor systems are particularly useful, allowing visualization of surgical area; moreover, fine, proper surgical instruments are also mandatory. When performing celiotomy a standard midline incision is made through the skin, subcutis, and linea alba. The abdominal wall should be carefully lifted with fine forceps, and Metzenbaum scissors may be used to make a small incision in the linea alba for entering the abdominal cavity. During surgery, any exposed parts of the gastrointestinal tract should be moistened or covered with surgical swabs soaked with warm fluids. The skin is extremely thin/fine on the ventral abdomen, and there is often a very small amount of subcutaneous fat present. For surgical interventions in spiny skin area for tumour removal or wound treatment, removal of spines is necessary; they may be clipped or less commonly removed with steady traction at the base. Absorbable materials are recommended for sutures in African pygmy hedgehog; braided absorbable suture material like polyglycolic acid for skin and suitable absorbable monofilament materials for internal organs. Since African pygmy hedgehogs mostly do not traumatize surgical skin incisions, an Elizabethan collar is not practical in this species. To conclude, African pygmy hedgehogs are commonly presented for a variety of diseases with an indication for surgical intervention. The most common conditions include reproductive disorders (ovariohysterectomy), excision of various tumours and abdominal explorative surgery for organ examinations and obtaining biopsies.

METHODS FOR DETECTION OF NON-CULTIVABLE VIRUSES IN FOODS

Branko Velebit, DVM, PhD

Department of Microbiology and Molecular Biology, Institute of Meat Hygiene and Technology, Belgrade, Serbia

Foodborne viruses, particularly human norovirus (HuNoV) and hepatitis A virus (HAV), represent a major analytical and regulatory challenge nowadays due to their low infectious dose, environmental persistence, and the absence of routinely applicable cell culture systems for food matrices. Detection methodologies are therefore based on molecular identification of viral nucleic acids rather than direct demonstration of infectivity. From a regulatory perspective, virus testing is applied primarily to foods recognized as high risk based on epidemiological evidence and exposure pathways. These include bivalve mollusks, berries, and leafy green vegetables, all of which are prone to contamination through contact with human fecal material via contaminated water, environmental exposure, or infected food handlers. Current standardized methodologies aim to support surveillance, outbreak investigation, and verification of control measures rather than definitive assessment of consumer risk.

Detection of foodborne viruses consists of two essential analytical stages: i) sample preparation, including virus elution, concentration, purification, and nucleic acid extraction and, ii) molecular detection, most commonly by reverse transcription quantitative PCR (RT-qPCR). Unlike bacterial food safety testing, viral methods do not include an enrichment step since viruses are inanimate objects and must therefore address low target concentrations and heterogeneous distribution within food lots. The analytical sensitivity of virus detection is primarily determined by the efficiency of virus recovery and the extent of residual matrix-associated inhibition affecting enzymatic amplification.

Bivalve mollusks (e.g., oysters, mussels, clams) are recognized globally as a major vehicle for foodborne viral transmission. Their filter-feeding behavior leads to bioaccumulation of viruses from contaminated waters, particularly in the digestive diverticula (hepatopancreas). From a methodological standpoint, this allows targeted processing of specific tissues rather than whole-product elution. Virus detection in bivalves is generally associated with higher positivity rates and lower quantification cycle (Cq) values compared to produce, reflecting both higher virus loads and more homogeneous distribution. Consequently, bivalves are frequently used as reference matrices in method development and validation, including ISO 15216. In contrast, berries represent a technically challenging matrix due to surface-localized contamination, low virus recovery efficiency, and strong matrix inhibition. Virus distribution is often highly heterogeneous, and recovery efficiencies below 10% are commonly reported even when standardized methods are applied. Freezing has minimal impact on viral RNA detectability or infectivity, further complicating interpretation of test results. Leafy greens (e.g. lettuce, spinach, green onions) share several methodological challenges with berries, including surface contamination and matrix inhibition. However, their larger surface area, frequent irrigation, and handling during harvest increase the likelihood of diffuse contamination. Virus detection

methods for leafy greens generally rely on elution-based approaches similar to those used for berries but may exhibit different inhibition profiles.

The ISO 15216 standards constitute the primary internationally recognized methods for detection (Part 2) and quantification (Part 1) of HuNoV and HAV in foods. These standards cover bivalve mollusks, berries (soft fruits), leafy greens, bottled water, and food contact surfaces. Key methodological elements include:

- Matrix-specific virus elution strategies
- Virus concentration (e.g., PEG precipitation)
- Organic solvent purification
- Guanidine thiocyanate-based RNA extraction
- RT-qPCR targeting conserved genomic regions

ISO 15216 places strong emphasis on the use of process control viruses, amplification controls, and clearly defined acceptance criteria for PCR inhibition and extraction efficiency, reflecting the high uncertainty inherent to Poisson-distributed viral contamination, methodological constraints, and the need to balance the risk of false-positive results, which may impose disproportionate burdens on food business operators, against false-negative outcomes that may pose public health risks to consumers. The standards also allow a certain degree of flexibility in reagents and platforms, provided performance requirements are met, which facilitates broad implementation but introduces potential inter-laboratory variability. In addition to the ISO 15216 standard, the United States applies the FDA Bacteriological Analytical Manual (BAM) Chapter 26 method, which, in contrast to the ISO approach, constitutes a highly prescriptive national protocol incorporating ultracentrifugation for virus concentration and mandatory multi-step RNA purification. While analytically robust, its applicability is constrained by equipment requirements and reduced methodological flexibility.

A critical consideration in virus detection is the non-uniform distribution of viruses within and between production lots. Viral contamination events are often stochastic and localized, particularly when associated with infected food handlers or point-source water contamination. From a statistical perspective, virus occurrence in foods frequently follows a Poisson or over dispersed distribution, where the probability of detection is strongly influenced by: i) sample size, ii) number of analytical units tested and iii) spatial distribution of contamination. As a result, negative test results do not guarantee absence of contamination, and single-sample testing has limited predictive value for lot compliance. This has important regulatory implications for sampling plans, particularly for commodities such as berries and leafy greens, where contamination may be present in discrete “hot spots”. Further complexity in the interpretation of results within a risk assessment context arises from the fact that all currently standardized methods detect viral RNA rather than infectious virus. RT-qPCR positivity may reflect intact infectious particles, damaged virions, or residual nucleic acid persisting after inactivation. Consequently, there is no direct, validated correlation between C_q values and public health risk. This limitation is particularly relevant at high C_q values, where detected RNA may represent fractions of an infectious unit or none at all. While cell culture-based infectivity assays exist for HAV, they are not routinely applicable to food testing, and no comparable system is available for HuNoV. This infectivity dilemma remains a central constraint in regulatory interpretation of virus testing results.

In light of emerging biomolecular techniques, digital RT-qPCR offers absolute quantification without reliance on standard curves and may provide improved tolerance to PCR inhibitors. Preliminary studies indicate potential benefits for low-level detection in complex matrices. However, limitations include higher cost, lower throughput, and unresolved questions regarding result comparability with established RT-qPCR methods. Also, NGS is increasingly recognized as a powerful tool for outbreak investigation, strain characterization, and source attribution. While not suitable for routine screening due to sensitivity constraints, NGS can differentiate outbreak strains from background contamination, but also support linkage between food, clinical, and environmental samples and identify contamination pathways retrospectively. Presently, integration of NGS with RT-qPCR screening represents a promising approach for enhanced surveillance and epidemiological resolution.

In conclusion, current detection methodologies for foodborne viruses are scientifically mature but intrinsically limited by reliance on molecular detection of viral RNA. ISO 15216 provides a harmonized framework for testing across high-risk foods, including bivalve mollusks, berries, and leafy greens. However, challenges related to heterogeneous virus distribution, low recovery efficiency, and inability to assess infectivity constrain the regulatory interpretation of results. Emerging technologies such as digital RT-qPCR and NGS offer complementary tools for improved quantification and outbreak tracking but do not replace the need for preventive controls as the primary risk management strategy.

ANTIMICROBIAL RESISTANCE IN FOOD-PRODUCING ANIMALS: FOOD SAFETY AND ONE HEALTH APPROACH

Ivan Vičić, DVM, PhD

Department of Food Hygiene and Technology, Faculty of Veterinary Medicine, University of Belgrade, Belgrade, Serbia

The development of antimicrobial resistance (AMR), resulting from the inappropriate use of antimicrobial agents across various niches, from agricultural production to human and veterinary medicine, is an emerging issue worldwide, leading to economic losses in production and ultimately to the deaths of individuals. Although almost two-thirds of the world's antimicrobial production is intended for use in food-producing animals, it remains unclear to what extent AMR arises and can be transmitted to humans.

The use of antibiotics, as well as the presence of AMR in farm animals, shows distinct spatial patterns, with penicillins, sulfonamides, and tetracyclines generally being the most widely used. The misuse or overuse of antibiotics leads to the emergence of resistance in various pathogenic bacteria of importance in the food chain, such as *Salmonella*, *Campylobacter* spp., Shiga toxin-producing *E. coli*, *Yersinia enterocolitica*, *Listeria monocytogenes*, and *Staphylococcus aureus*. While trends in the prevalence of pathogenic microorganisms have changed over time, the complexity of AMR lies in the fact of the selective pressure on the microbiome of food-producing animals, with horizontal transfer of resistance genes and a series of mutations leading to the emergence of resistant commensal, non-pathogenic bacteria, which spread further along the food chain.

Reducing disease incidence in food-producing animals, strengthening biosecurity measures at the farm level, monitoring antimicrobial drug use, and surveillance of AMR in pathogenic and non-pathogenic microorganisms are among the mechanisms for reducing AMR and advancing the One Health concept.

Keywords: antibiotics; pathogenic bacteria; commensal microorganisms; resistance genes; food chain.

Funding: This study was supported by the Science Fund of the Republic of Serbia, Grant No. 7042, Tracking antimicrobial resistance in diverse ecological niches - one health perspective - TRACE.

THE DELICATE ROLE OF BIOSECURITY IN MODERN POULTRY PRODUCTION

Giuditta Tilli, DVM, PhD

Vetworks BV, Poeke, Belgium

Biosecurity measures (BMs) are fundamental to preventing and controlling infectious diseases in poultry production. They encompass external and internal biosecurity, structural and operational practices, and farm-specific routines that collectively reduce pathogen introduction and spread. Their importance lies in safeguarding flock health, maintaining productivity, and ensuring food safety; when inadequately implemented, BMs can lead to increased pathogen circulation, reduced performance, economic losses, and heightened antimicrobial use. Within the European Union, several BMs are mandatory under the regulatory framework governing animal health, hygiene, and disease prevention, requiring farms to adopt BMs for cleaning and disinfection (C&D), water hygiene, pest control, and movement management as major attention points. In parallel, different risk-based scoring systems and predictive tools to objectively assessing BMs levels and guide targeted improvements are available.

Against this background, a persistent gap exists between BMs implemented and BMs complied with in field conditions. To better understand and address this gap, several complementary approaches are proposed, including field-based evaluations supported by new technologies, assessment of personality traits, education level, and willingness to change among farm operators, implementation of effective and continuous training tools, and the use of field-derived evidence on BMs and the return on investment (ROI) associated with their proper adoption.

Therefore, the purpose of this presentation is to integrate findings from different and complementary field and literature studies assessing biosecurity implementation on commercial poultry farms. Among field studies, studies focused on the effectiveness of C&D procedures on drinking water hygiene and poultry houses will be presented, as well as different methodologies used to assess their implementation (e.g., use of visual inspections, ATP and protein swabs, microbiological and viral analyses of key surfaces).

Overall, this presentation contributes to the limited body of field-based biosecurity research by incorporating the latest findings from field studies, providing a state-of-the-art overview of biosecurity in poultry production, and underscoring its critical role in protecting flocks. However, biosecurity ultimately depends on people, making it crucial to incorporate human behaviour, training, and awareness into every hygiene and biosecurity plan.

THE ECONOMICS OF DISEASE IN DAIRY PRODUCTION – WHY INVESTING IN A VETERINARIAN IS OF VALUE

Melanie Schären-Bannert^{1,2}, Peter Hufe³, Adriana Wöckel², Wolf Wippermann², Benno Waurich⁴, Erik Bannert⁵, Julia Wittich³, Christina Felgentreu³, Franz Fröhlich³, Fanny Rachidi², Detlef May³, Sven Dänicke⁵, Hermann H. Swalve⁴, Alexander Starke²

¹Unit for Herd Health Management, Clinical Department for Farm Animals and Food System Science, University of Veterinary Medicine Vienna - Vetmeduni, Vienna, Austria

²Clinic for Ruminants and Swine, Faculty of Veterinary Medicine, University of Leipzig, Leipzig, Germany

³LVAT – Institute for Animal Breeding and Husbandry, Groß Kreutz, Germany

⁴Institute of Agricultural and Nutritional Sciences, University of Halle, Halle-Wittenberg, Germany

⁵Institute of Animal Nutrition, Friedrich-Loeffler-Institute (FLI), Federal Research Institute for Animal Health, Brunswick, Germany

Decisions in animal health economics are made daily in dairy production at both the individual animal level (e.g., treatment or culling) and the herd level (e.g., prophylaxis). Collaboration between farmer and veterinarian is central, yet robust data for well-founded decisions are often lacking. In culling decisions there is a frequent bias toward replacement rather than treatment, promoting high culling rates, which is problematic for welfare and sustainability and suspected to be economically suboptimal. Therefore, the aim of a project conducted in Brandenburg, Germany between 2018-2023 was the generation of standardized, real-world on-farm data on the costs of diseases and associated foregone revenues to provide a robust empirical basis for practice-oriented decision-making.

Twelve Brandenburg farms with an average of 574 German Holstein cows and a culling rate of 31.4% (23.0–42.4%, adjusted for breeding stock sales) were monitored for five years; lifetime yield of culled cows averaged 31,619 kg (24,771–42,249 kg). Economic data derived from quarterly enterprise analyses and targeted acquisitions focused on the share of animal health costs in production costs, claw health costs, and costs of single-animal diseases.

Animal health costs averaged €2.12/dt ECM (2021): veterinary services €0.33, employed veterinarians €0.02, pharmaceuticals €0.90, udder care €0.06, laboratory €0.07, disposal €0.06, pre-slaughter costs €0.12, claw trimming €0.56. Pharmaceuticals accounted for 42.4%, veterinary services 15.6%, and claw-related services/expenditures 26.4%. No relationship was found between herd-level animal health costs and milk production level or culling rate. The two farms with the lowest culling rates (23.2% Farm X; 23.0% Farm P) showed the lowest (Farm X: €1.27/dt ECM) and the highest animal health costs (Farm P: €4.42/dt ECM), respectively; Farm P's high spending reflected intensive prophylaxis and early action. Farm X combined low culling and low health spending with the marketed milk production level (10,605 kg ECM; mean 9,974 kg ECM).

Claw health costs comprised herd trimming/routine €0.21/dt ECM, orthopedics/treatment €0.12, employed claw trimmers €0.06, pharmaceuticals/biocides/care €0.01, trimming

materials €0.05, footbath materials €0.11. Expenditures averaged €56.20 per cow and year (2020: €58.34; 2019: €53.23).

For single-animal disease costs, ten farms underwent intensive three-week recordings between May 2020 and June 2021. A total of 3,724 diagnoses (138 combinations) were documented, with 22,631 product applications, and time recorded for 6,350 examinations and 821 treatments. After excluding incomplete datasets, 1,272 cases had itemized costs and foregone revenues (time, products, veterinary and orthopedic services, production loss, reduced performance, culling, book loss, foregone slaughter value). In 68% of cases a single organ system was affected, 11% had multiple diagnoses within one organ, and 21% involved multiple systems; summed costs often potentiated. For mastitis (means; min–max): acute catarrhal total €403 (€88–€2,045), phlegmonous €594 (€124–€1,429), abscessing €673 (€262–€1,195). Literature comparisons showed similar magnitudes and proportions; labor effort was often higher than previously described. Costs and foregone revenues from production loss, reduced performance, and culling frequently exceeded diagnostic and treatment costs, indicating substantial potential for prevention and treatment. For displaced abomasum, treatment expenditure was 12.2% of total costs and foregone revenues, attributed to frequent use of lower-cost but riskier methods (conservative or percutaneous fixation). Costs depended significantly on diagnostic and treatment quality; key risk factors included availability of veterinary professionals and inadequate workplace design or treatment areas, whose implementation requires investment and is often challenging under difficult economic conditions.

Enterprise-level animal health costs, due to complexity and multifactorial influences, do not allow inference about the health situation. Farms with good animal health management can achieve high milk performance with low health costs through targeted management and prevention. Veterinary services currently play a subordinate role in cost structure compared to pharmaceuticals, while single-animal cost structures reveal potential for preventive and therapeutic measures (including surgical). The costs and extent of foregone revenues depend on the quality of diagnosis and treatment; qualifications and workplace design are decisive.

PAIN MANAGEMENT IN CALVES

Cassandra Eibl, PhD, Dipl. ECBHM

Clinical Department for Farm Animals and Food System Transformation, Clinical Centre for Ruminants, Camelids and Herd Health Management, University of Veterinary Medicine, Vienna, Austria

Calves pass through several critical periods on their way to adulthood. These periods may be associated with dystocia requiring forceful traction or diseases such as neonatal diarrhoea, umbilical disorders, or abomasal ulcers, or with management-related interventions such as disbudding. These episodes often have one feature in common: they cause varying degrees of pain to the animals.

It is the responsibility of veterinarians to recognize and appropriately manage this issue; However, the treatment of pain in large animals still appears to be less than optimal as it remains a challenge for many veterinarians. According to Mijares et al. (2023) pain assessment in pre-weaned calves with bovine respiratory disease (BRD) was not routinely performed by all veterinarians. Only 53% of surveyed veterinarians reported assessing pain in these calves. Among those who did assess pain, just 40% considered their ability to recognize pain to be adequate. Lorena et al. 2013 reported, that more veterinarians who had graduated within the last 10 years used NSAIDs than those who had graduated >10 years ago, independent the case. Reported barriers to analgesic use include limited competence in pain assessment in animals as well as uncertainty about appropriate dosages and pharmacological effects (Flecknell 2008). Kielland et al. 2009 reported, that pain assessment is gender dependent, women assigned higher pain scores than men.

For objective pain scoring several assessments based on different parameters (e.g. grimace scales, locomotion score) had been published (de Olivera et al. 2014, Gleerup et al. 2015). Successful treatment requires not only knowledge of the available pharmacological agents and their mechanisms of action, but also an understanding of the underlying nature of pain. Appropriate pain management depends on distinguishing between different pain types, since analgesic efficacy varies according to the type of pain involved. Different tools for assessment as well the sufficient management of pain will be discussed during presentation.

MONITORING REPRODUCTIVE PERFORMANCE AND FERTILITY PROBLEMS IN DAIRY COWS

Prof. Harald Pothmann, DVM, PhD, Dipl. ECBHM, Dipl. EBS

Clinical Department Farm Animals and Food System Science, University of Veterinary Medicine Vienna – Vetmeduni, Vienna, Austria

Efficient fertility management is a critical determinant of biological and economic performance in dairy herds, yet it remains one of the most complex aspects of herd management.

Modern dairy herds generate enormous quantities of reproductive data, including calving dates, inseminations, pregnancy diagnoses, and culling reasons. Advances in herd recording systems have made it technically feasible to collect and store these data accurately and consistently. However, the existence of data does not guarantee improved fertility outcomes. The challenge lies in transforming raw data into meaningful information that can guide timely and appropriate management actions.

There is importance of clearly defined fertility targets and performance indicators. Measures such as calving interval, days to first service, conception rate, and submission rate are commonly used, but each has limitations if interpreted in isolation. Poor fertility performance often results from multiple interacting factors, including nutrition, health, environment, and management, which cannot be diagnosed using a single metric.

Fertility problems rarely occur in isolation, and linking reproductive performance with other datasets can help identify underlying causes, such as metabolic disease (e.g., hypocalcemia and ketosis) in early lactation or management-related stressors. A major advance has been redefining disease more broadly, to include subclinical conditions, e.g., subclinical mastitis, ketosis, rumen acidosis, and endometritis.

Reproductive management continued to be a fundamental task but evolved from focus on problems of individual cows to systematic programs to prevent uterine disease and efficiently inseminate nonpregnant cows. In veterinary herd health management, control points of the reproduction cycle are used to determine cows at risk, which are regularly introduced to the serving veterinarians. Regular checks include close-up cows, fresh cows and animals within and past voluntary waiting period if not been inseminated yet. The aim of this procedure is to early detect subclinical and clinical disease, non-pregnancy and to implement targeted reproductive management. Among uterine diseases, puerperal metritis usually occurs within 10 days after parturition and is an acute systemic illness, characterized by a fetid red-brown watery uterine discharge. Clinical endometritis is characterized by the presence of purulent (>50% pus) or mucopurulent (approximately 50% pus, 50% mucus) uterine exudate in the vagina, 21 days or more post-partum, and is not accompanied by systemic signs. Endometrial inflammation of the uterus in the absence of purulent material in the vagina defines subclinical endometritis. It can be evaluated by cytological examination techniques, including endometrial cytobrush sampling and microscopic evaluation of inflammatory cell counts. The incidence of clinical and subclinical endometritis is approx. up to 50% at 40–60 days post-partum and is associated with delayed conception and increased culling. It is proposed that subclinical endometritis is defined by >18%

neutrophils in uterine cytology samples collected 21–33 days post-partum, or >10% neutrophils at 34–47 days. However, thresholds of neutrophils for definition of subclinical endometritis vary between studies applying different sampling methods, days of sampling, and association to reproductive performance.

Veterinarians acquire new analytical skills, including the application of (Doppler) ultrasound technique to determine early pregnancy, twin fetuses, sexing of fetuses, early pregnancy losses and various stages of estrous cycle. This contributes to a more comprehensive reproduction management to enhance effective veterinarian advisory.

SMALL ANIMALS SESSION
ORAL PRESENTATIONS

CHRONIC ORONASAL FISTULA IN A DOG ASSOCIATED WITH A MINERALISED NASAL FOREIGN BODY - A CASE REPORT

Mirta Vučković^{1*}, Mirta Paić Radovniković², Željka Stepanić¹, Marija Mamić¹

¹*Clinic for Surgery, Orthopaedics and Ophthalmology, Faculty of Veterinary Medicine, University of Zagreb, Zagreb, Croatia*

²*Veterina Branimir d.o.o., Zagreb, Croatia*

**corresponding author: Mirta Vučković, mirta.vuckovic@vef.unizg.hr*

Pain during eating and unilateral or persistent nasal discharge are key clinical indicators that necessitate a thorough dental examination, as oral and dental pathology frequently underlies maxillofacial disease in dogs.

A 17-year-old male Maltese was presented with a two-year history of intermittent purulent discharge from the right nostril, periodically managed with antibiotics, and a recent onset of pain during feeding. Clinical examination revealed marked maxillary pain, mobility of the right maxillary canine and adjacent premolars and molars, gingival inflammation, and foul-smelling unilateral nasal discharge.

Dental examination revealed mobility of teeth 103–107. An increased gingival sulcus depth of 8 mm was recorded at tooth 104, where a clinically evident oronasal fistula was also observed. Intraoral radiography revealed a radiopaque mineralised structure consistent with a foreign body located at the apex of 104 and extending around 105–107, accompanied by advanced alveolar bone loss. The presence of the foreign material likely contributed to chronic infection, progressive periodontal destruction, and fistula formation.

Open surgical extraction of teeth 103–107 was performed. Intraoperatively, the oronasal fistula and mineralised foreign material were identified and removed. Reconstruction was achieved using a mucogingival pedicle flap to re-establish functional separation between the oral and nasal cavities. Postoperative management included analgesia and home-based oral hygiene. Healing progressed without complications, and nasal discharge resolved completely.

This case emphasises the diagnostic importance of dental evaluation in dogs presenting with nasal discharge and oral pain. Chronic periodontal disease, particularly when exacerbated by an unrecognised foreign body, can lead to extensive maxillofacial pathology. Early identification and timely surgical management are essential for successful clinical outcomes.

Keywords: oronasal fistula, canine, foreign body, dental radiography, periodontal disease, surgical reconstruction

EPIDEMIOLOGICAL, CLINICAL, AND LABORATORY CHARACTERISTICS OF ADRENAL TUMORS IN DOGS AND CATS: A SINGLE-CENTER RETROSPECTIVE STUDY (2022–2025)

Katarina Marjanović^{1*}, Elizabeta Pongrac¹, Magdalena Bogović¹, Branko Petričević², Iva Šmit¹, Martina Crnogaj¹, Marin Torti¹

¹*Clinic for Internal medicine, Faculty of Veterinary Medicine, University of Zagreb, Zagreb, Croatia*

²*Clinic for Surgery, Orthopaedics and Ophthalmology, Faculty of Veterinary Medicine, University of Zagreb, Zagreb, Croatia*

**corresponding author: Katarina Marjanović, kmarjanovic@vef.unizg.hr*

Adrenal tumors in dogs and cats are uncommon and present with variable clinical signs. In dogs, the most frequent types are cortisol-secreting adrenocortical tumors and catecholamine-secreting pheochromocytomas, although hormonally inactive masses also occur. In cats, aldosterone secreting tumors predominate.

This retrospective study included 37 dogs and 1 cat diagnosed with adrenal tumors at the Clinic for Internal Diseases, Faculty of Veterinary Medicine, University of Zagreb, between January 2022 and October 2025. Collected data comprised signalment, presenting complaints, laboratory findings, imaging results, treatment, and histopathology when available.

The main inclusion criterion was the presence of an adrenal mass. Most dogs were older (median age 11 years), with females overrepresented (22/37). Mixed-breed dogs were most common. Tumors were more frequently located in the left adrenal gland (24/36). Surgical treatment was performed in 12 dogs, medical treatment in 8, while 17 dogs received no treatment. Histopathology (n=11) revealed adrenocortical carcinomas (4/11), adenomas (3/11), and pheochromocytomas (4/11). The most frequent laboratory abnormalities were increased alanine aminotransferase and alkaline phosphatase activities, while endocrine testing showed variable diagnostic value.

These results, taking into account the retrospective nature of the study, inconsistent diagnostic workup and limited histopathological data, indicate that adrenal tumors in this referral population primarily affect older dogs and are histologically heterogenous. Observations of left-sided lesions and a femal majority are reported for this cohort but require confirmation in large, standardized studies. We recommend standardized, multimodal diagnostic approach to improve characterisation and management of adrenal neoplasms.

Keywords: adrenal tumors; dog; pheochromocytoma; adrenocortical carcinoma; adrenocortical adenoma; endocrine diagnostics, histopathology

GALLBLADDER MUCOCELE IN DOGS: A RETROSPECTIVE STUDY OF CLINICAL AND HISTOPATHOLOGICAL FEATURES

Elizabeta Pongrac^{1*}, Branko Petričević², Magdalena Bogović¹, Katarina Marjanović¹, Maša Efendić¹, Lucija Jeremić¹, Ivana Kiš¹, Martina Crnogaj¹

¹*Clinic for Internal Diseases, Faculty of Veterinary Medicine, University of Zagreb, Zagreb, Croatia*

²*Clinic for Surgery, Orthopedics and Ophthalmology, Faculty of Veterinary Medicine, University of Zagreb, Zagreb, Croatia*

**corresponding author: Elizabeta Pongrac, epongrac@vef.unizg.hr*

Gallbladder mucocele (GBM) is an increasingly recognized hepatobiliary disorder in dogs, characterised by abnormal accumulation of mucin within the gallbladder. Despite its clinical significance, detailed retrospective analyses of clinical and histopathological features remain limited. This study aimed to characterize the clinical presentation, biochemical alterations, histopathological findings, and postoperative outcomes in dogs that underwent cholecystectomy for GBM.

Medical records from the Clinic for Internal Diseases and the Clinic for Surgery, Orthopaedics, and Ophthalmology at the Faculty of Veterinary Medicine, University of Zagreb, were retrospectively reviewed to collect data on all dogs that underwent cholecystectomy due to ultrasonographically diagnosed gallbladder mucocele between January 2023 and September 2025. A total of 23 dogs were included, predominantly Maltese (26%), Miniature Schnauzers (22%), and mixed breeds (22%), with a median age of 11 years. Frequently observed biochemical abnormalities included elevated gamma-glutamyl transferase (83%), alanine aminotransferase (78%), and alkaline phosphatase (78%), hypercholesterolemia (74%) and hypertriglyceridemia (61%). Histopathological (PHD) examination showed gallbladder mucocele in 50% and cystic mucosal hyperplasia in 27% of cases. Hepatic PHD predominantly included vacuolar hepatopathy (27%), chronic hepatitis (27%), and cholangiohepatitis (19%). Gallbladder rupture with bile peritonitis was identified in 13% of dogs. The postoperative mortality rate, among all dogs in the study was 13% and was associated with surgical complications.

Cholecystectomy remains the treatment of choice for GBM dogs, however, the procedure carries a certain risk, particularly in cases complicated by gallbladder rupture and bile peritonitis. Timely diagnosis, patient stabilization, and prompt surgical intervention are essential for a favorable treatment outcome.

Keywords: dog, gallbladder mucocele, cholecystectomy, histopathology

SIGNIFICANCE OF *CLOSTRIDIUM PERFRINGENS netE* AND *netF* TOXIN GENES IN DOGS WITH ACUTE DIARRHEA

Vanda Dučić^{1*}, Vesna Mojčec Perko², Iva Benvin², Josipa Habuš², Zrinka Štritof², Vladimir Stevanović², Matko Perharić², Iva Zečević², Krešimir Martinković², Suzana Hađina²

¹Oktal pharma d.o.o., Utinjska 40, Zagreb, Croatia

²Department of Microbiology and Infectious Diseases with Clinic, Faculty of Veterinary Medicine, University of Zagreb, Zagreb, Croatia

*corresponding author, ducicvanda97@gmail.com

Clostridium perfringens produces several toxins associated with canine gastrointestinal disease, including enterotoxin (CPE), which has been associated with acute hemorrhagic diarrhea syndrome (AHDS). Recent studies indicate that the pore-forming toxins NetE and NetF may play a significant role in the development of AHDS and could also contribute to non-hemorrhagic diarrhea. This study aimed to assess the presence of the *Clostridium perfringens netE* and *netF* toxin genes in dogs presenting with acute diarrhea and to investigate their potential association with AHDS.

Fecal samples or rectal swabs were collected from 128 dogs (40 healthy controls and 88 with diarrhea) and analyzed for the presence of *netE*, *netF* and *cpe* toxin genes using a conventional polymerase chain reaction. The *netE* and *netF* genes were detected in 27.8% (20/72) of dogs with watery diarrhea, 33.3% (2/6) of dogs with slightly soft feces, and 20% (2/10) of dogs with soft feces. Hemorrhagic diarrhea was present in 58.0% (51/88) of cases, with 35.3% (18/51) testing positive for *netE* and *netF*, compared with 16.2% (6/37) of non-hemorrhagic cases. Among dogs with hemorrhagic diarrhea, 66.7% (34/51) were diagnosed with AHDS; all *cpe*-positive, and 47.1% (16/34) had detectable *netE* and *netF* genes. In contrast, none of the healthy dogs had detectable *netE* or *netF* genes, while 70% were positive for *cpe* genes.

The results show that *Clostridium perfringens* strains encoding *netE* and *netF* genes are significantly more prevalent in fecal samples from diarrheic dogs, especially those with AHDS, than in healthy individuals. These findings provide additional evidence for the involvement of *netE* and *netF* toxin genes in the pathogenesis of AHDS and expand our understanding of their role in canine acute non-hemorrhagic diarrhea, which requires further investigation.

Keywords: *Clostridium perfringens*, *netE* and *netF* toxin genes, diarrhea, acute hemorrhagic diarrhea syndrome

QUANTITATIVE SHEARWAVE ELASTOGRAPHY OF THE CANINE PROSTATE: A COMPARATIVE CLINICAL ASSESSMENT OF HEALTHY TISSUE, INTRAPROSTATIC CYSTS AND BENIGN PROSTATIC HYPERPLASIA

Ivan Tomić^{1*}, Maša Efendić², Ivan Butković¹, Juraj Šavorić, Tugomir Karadjole, Martina Lojkić¹

¹*Clinic for Obstetrics and Reproduction, Faculty of Veterinary Medicine, University of Zagreb, Zagreb, Croatia*

²*Clinic for Internal Diseases, Faculty of Veterinary Medicine, University of Zagreb, Zagreb, Croatia*

**corresponding author: Ivan Tomić, itomic2@vef.hr*

Shear-wave elastography (SWE) is increasingly used as a complementary ultrasound technique for objective assessment of tissue stiffness; however, quantitative comparative data for common canine prostatic conditions remain limited. This pilot observational case series included three dogs (n = 3): one with a healthy prostate, one with intraprostatic cysts and one with benign prostatic hyperplasia (BPH). Transabdominal SWE was performed using a high-end ultrasound system (Philips EPIQ Elite), with three measurements obtained from each prostatic lobe and averaged to yield one representative stiffness value per dog (kPa). Mean prostatic stiffness was lowest in the healthy dog (30 kPa), moderately increased in the dog with intraprostatic cysts (37 kPa), and highest in the dog affected by BPH (46.8 kPa). This progressive increase in tissue stiffness reflects underlying structural and stromal changes associated with prostatic pathology.

The novelty of this study lies in the direct quantitative comparison of SWE values across different prostatic conditions within a standardized measurement protocol. SWE may provide additional diagnostic value when B-mode ultrasonographic findings are inconclusive and may support monitoring of disease progression.

Keywords: dog, prostate, shear-wave elastography, SWE, benign prostatic hyperplasia, cysts

SMALL ANIMALS SESSION
POSTER PRESENTATIONS

A CASE OF PERSISTENT DECIDUOUS CANINE TOOTH IN A DOMESTIC CAT

Petra Ricijaš^{1*}, Ana Gross², Marija Lipar¹

¹Clinic for Surgery, Orthopedics and Ophthalmology, Faculty of Veterinary Medicine, University of Zagreb, Zagreb, Croatia

²Faculty of Veterinary Medicine, University of Zagreb, Zagreb, Croatia

**corresponding author: Petra Ricijaš, pricijas@vef.unizg.hr*

Persistent deciduous teeth are a rare finding in feline patients. They may occur due to a lack of a permanent successor, ankylosis of the tooth to the alveolus, failure of permanent and deciduous tooth interaction during eruption, or hormonal influences affecting metabolism and growth. A 1.5-year-old domestic male cat was presented with halitosis, food debris retention due to malocclusion, and gingival inflammation in the area of the left maxillary canine tooth. Clinical examination revealed a fistulous tract filled with food remains and a mobile deciduous left maxillary canine tooth, while the remaining dentition appeared normal. Radiographic evaluation confirmed retention of the left maxillary deciduous canine tooth without evidence of periapical pathology. The permanent left maxillary canine tooth was visualized radiographically and showed no pathological changes. Hematology and serum biochemistry results were within reference ranges, except for mild eosinopenia and a 15% increase in globulin levels. The cat was premedicated intravenously with methadone (0.2 mg/kg) and dexmedetomidine (1 µg/kg), anesthesia induced with ketamine (0.5 mg/kg) and propofol (4 mg/kg), and maintained with isoflurane. Left infraorbital nerve block using levobupivacaine (0.3 mg/kg) was performed for multimodal analgesia. The retained deciduous canine was surgically extracted without complications. Postoperative analgesia included meloxicam, and recovery was uneventful. One month after surgery, no recurrence of purulent discharge or clinical signs were observed. Persistent deciduous teeth in cats are uncommon and may cause secondary oral pathology, including fistula formation, malocclusion, and food retention. Early recognition and extraction are essential to prevent long-term complications and discomfort.

Keywords: cat, deciduous tooth retention, feline dentistry, oral surgery

COMPARATIVE ANALYSIS OF THREE VALIDATED DOG BEHAVIOUR AND PERSONALITY QUESTIONNAIRES: C-BARQ, DPQ, AND PANAS

Mihaela Vranješ Delač^{1*}, Gabrijela Jurkić Krsteska², Ivana Kiš²

¹PhD student, Faculty of Veterinary Medicine, University of Zagreb, Zagreb, Croatia

²Clinic for Internal Diseases, Faculty of Veterinary Medicine, University of Zagreb, Zagreb, Croatia

**corresponding author: Mihaela Vranješ Delač, mvranches@vef.hr*

Understanding emotions, motivations, and innate temperament is essential for accurate behavioural assessment of dogs in veterinary medicine. These factors influence daily functioning, the dog-owner relationship, work suitability, and the risk of developing behavioural problems. Timely and precise assessment is crucial not only for selecting therapeutic strategies but also for improving welfare in domestic and working environments. Validated owner-reported questionnaires have been developed to enable standardised and objective evaluation of behavioural and emotional traits.

This study presents a descriptive, literature-based comparative analysis of three widely used and validated instruments: the Canine Behavioural Assessment and Research Questionnaire (C-BARQ), the Dog Personality Questionnaire (DPQ), and the Positive and Negative Activation Scale for Dogs (PANAS). The comparison focuses on each tool's theoretical foundation, structure, psychometric properties, and practical application.

The latest version of C-BARQ includes 100 items grouped into 14 behavioural factors and several discrete behaviours. The full DPQ consists of 75 items arranged into 15 factors aligned with five personality dimensions. The canine-adapted PANAS comprises 21 items measuring two emotional activation dimensions: positive and negative. All three instruments were developed using robust psychometric methods and demonstrate good internal consistency (Cronbach's $\alpha > 0.70$) and acceptable test-retest reliability.

Despite differences in scope and length, these questionnaires provide complementary insights: C-BARQ assesses a broad range of behavioural traits, DPQ captures personality dimensions, and PANAS targets core emotional tendencies. Each can be used independently depending on the assessment aim, while their combined use enables a more comprehensive understanding of canine behaviour and temperament.

Keywords: dog, behaviour, temperament, emotion, C-BARQ, DPQ, PANAS

A RETROSPECTIVE SURVEY ON CANINE INTRACRANIAL TUMORS BETWEEN 2015 AND 2025

Iva Cayden Gabrić^{1*}, Ivana Mihoković Buhin², Ivan-Conrado Šoštarić-Zuckermann², Branka Artuković², Dunja Vlahović², Lidija Medven Zagradišnik², Iva Ciprić², Andrea Gudan Kurilj², Doroteja Huber²

¹student, Faculty of Veterinary Medicine, University of Zagreb, Zagreb, Croatia

²Department of Veterinary Pathology, Faculty of Veterinary Medicine, University of Zagreb, Zagreb, Croatia

*corresponding author: Iva Cayden Gabrić, igabric@vef.hr

Intracranial tumors (IcT) include a diverse group of benign and malignant tumors of the brain and its associated structures. Although rare, these tumors present an important cause of morbidity and mortality in dogs, which, due to nonspecific signs and poor prognosis, pose diagnostic challenges. Despite improved diagnostics, IcT in dogs remain a relatively underexplored area of veterinary medicine.

The archive of the Department of Veterinary Pathology was reviewed for necropsied dogs diagnosed with IcT between 2015 and 2025. Assessed parameters were: age, sex, breed, tumor site, and histological type.

Among 7106 patients, 306 were diagnosed with a tumor, of which 10 cases (0.14% of all patients and 3.3% of tumor diagnoses) involved IcT. Eight (80%) IcT were primary tumors, and two (20%) were metastatic tumors. Primary IcT were mainly gliomas (75%), then meningioma and medulloblastoma (12.5% each). Metastatic IcT included a bronchoalveolar carcinoma (1 dog) and a hemangiosarcoma of the right auricle (1). The location of IcT were: meninges (1), base of the brain (1), both lateral ventricles (2), right frontal lobe (3), and temporal lobe (2). For one primary IcT, the location was not recorded. Metastatic IcT affected the cerebellum (1) and multifocal areas in the cerebrum and cerebellum (1). Sex ratio was 1:1 in both groups. Mean age was: primary 6.3 y (range 2–11 y.), metastatic 12.5 y (12–13). Breeds diagnosed with primary IcT were: mixed breed (1) and pure-breed (7). Breeds diagnosed with metastatic IcT were: mixed breed (1) and Canaan Dog (1).

This study examined epidemiologic and histologic data of canine IcT, confirming their rarity but clinical relevance given severe neurological signs and limited treatment options. In accordance with the literature, primary tumors, specifically gliomas, were the most common. Affected dogs were typically middle-aged to older, with no apparent sex predilection. Despite rarity, IcT in dogs warrant further diagnostic research.

Keywords: intracranial tumors, dog, histopathology, glioma

MODUS OPERANDI OF DOG ATTACKS IN DIFFERENT SPECIES

Magdalena Palić^{1*}, Nikola Serdar¹, Krešimir Severin¹

¹Department of Forensic and State Veterinary Medicine, Faculty of Veterinary Medicine, University of Zagreb, Zagreb, Croatia

**corresponding author: mpalic@vef.unizg.hr*

When an animal attack is suspected, after performing a necropsy and identifying bite wounds, it is necessary to determine the perpetrator. In addition to assessing the morphology of the injuries and measuring the spacing between canines, significant importance is placed on the attack pattern.

In recent years, the Department of Forensic and State Veterinary Medicine at the Faculty of Veterinary Medicine has handled several cases of dog attacks on other animal species, including dogs, peafowl, and deer. Before necropsy, X-ray imaging of the carcasses was performed. Necropsy was conducted to determine the cause, mechanism, and manner of death. In all cases, wounds on the skin were usually round or oval, with associated lacerations, abrasions, and contusions often affecting the subcutaneous tissue, muscles, and internal organs but with different attack patterns. It should be emphasised that due to the mobility of animal skin, more extensive injuries were found beneath the skin than were visible on the surface, known as the “iceberg effect.” Based on the morphology of the injuries and the attack patterns, it was concluded in all three cases that the perpetrator was a dog or a group of dogs.

It is important to note that dogs, depending on their temperament and learned behaviour, may either chase a victim away or attack with the intent to kill without consuming it. Depending on the victim, dogs also exhibit different attack patterns. When attacking another dog, they often bite randomly on various parts of the body, tearing and shaking the victim. In birds, injuries are predominantly on the lateral chest and wings, where inspection of the pectoral muscles reveals clear, often elliptical, bite marks, while in deer, injuries are mainly located on the hind limbs and lumbar area of the spine and sometimes on the ventral part of the neck. In deer, death may also result from severe capture myopathy, which can lead to kidney failure.

Keywords: dog, bite wound, dog attack, forensic pathology

SEROPREVALENCE OF *LEPTOSPIRA* SPP. IN CATS IN CROATIA

Iva Benvin^{1*}, Daniel Fitz², Vesna Mojčec Perko¹, Josipa Habuš¹, Zrinka Štritof¹, Dora Ivšić Škoda³, Suzana Hađina¹, Matko Perharić¹, Vladimir Stevanović¹, Krešimir Martinković¹, Iva Zečević¹, Ivona Ćorić¹, Gorana Miletić¹, Nenad Turk¹

¹*Department of Microbiology and Infectious Diseases with Clinic, Faculty of Veterinary Medicine University of Zagreb, Zagreb, Croatia*

²*Faculty of Veterinary Medicine University of Zagreb, Zagreb, Croatia*

³*Internal Medicine Laboratory, Faculty of Veterinary Medicine, University of Zagreb, Zagreb, Croatia*

**corresponding author: Iva Benvin, ibenvin@vef.unizg.hr*

Leptospirosis is a re-emerging zoonosis with worldwide distribution. Although found in various animal species and humans, the role of cats in the transmission dynamics has been largely underestimated and neglected. Understanding their contribution is crucial for public health.

A total of 264 archived sera from cats presented for various health problems at the Veterinary Teaching Hospital of the University of Zagreb in the period from January to June 2023 were analysed for *Leptospira* antibodies using the microscopic agglutination test (MAT). The antigen panel consisted of 12 pathogenic serovars: Grippotyphosa, Sejroe, Bratislava, Pomona, Canicola, Icterohaemorrhagiae, Tarassovi, Saxkoebing, Ballum, Bataviae, Poi and Hardjo. Samples with titres $\geq 1:50$ were considered seropositive.

Of the 264 serum samples tested, 49 (18.6%) had agglutinating antibodies against at least one serovar of *Leptospira* spp. and were classified as seropositive. The most common serogroup was Pomona in 18 (36.7%) samples, followed by Javanica, Sejroe, Gryppothyphosa and Australis in nine (18.4%), eight (16.3%), six (12.2%) and two (4.1%) samples, respectively. Icterohaemorrhagiae and Tarassovi were considered as presumptive infective serogroups in one (2%) serum sample, while in four sera (8.2%) with agglutination antibodies in the same titre against two serovars belonging to different serogroups, identification of the presumptive infectious serogroup was not possible, so these serum samples were classified as undetermined. The titres ranged from 1:50 to 1:12800.

In conclusion, the findings of this study highlight the substantial presence of *Leptospira* spp. infections in cats in Croatia, with Pomona emerging as the most common presumptive infectious serogroup. The overlooked importance of cats as reservoir hosts and the clinical impact of leptospirosis in feline populations highlight the need for further studies to clarify both their role in transmission and the effects of infection on feline health.

Keywords: *Leptospira* spp., serogroup Pomona, cat, MAT, seroprevalence, Croatia

FATAL MULTIPLE CONGENITAL MALFORMATIONS IN A POMERANIAN PUPPY- A CASE REPORT

Iva Lukša¹, Lidija Medven Zagradišnik², Ana Javor¹, Barbara Mratović¹, Petar Krolo³, Ivan Folnožić⁴, Zoran Vrbanac¹, Hrvoje Capak^{1*}

¹Department of Radiology, Ultrasound Diagnostic and Physical Therapy, Faculty of Veterinary Medicine University of Zagreb, Zagreb, Croatia

²Department of Veterinary Pathology, Faculty of Veterinary Medicine University of Zagreb, Zagreb, Croatia

³PhD student, Faculty of Veterinary Medicine University of Zagreb, Zagreb, Croatia

⁴Clinic for Reproduction and Obstetrics, Faculty of Veterinary Medicine University of Zagreb, Zagreb, Croatia

*corresponding author: Hrvoje Capak, hcapak@vef.unizg.hr

Congenital malformations are developmental abnormalities present at birth, arising from genetic, environmental, or nutritional factors. They may affect multiple organ systems and are a common cause of neonatal mortality. In multiparous species, individual fetuses within the same litter may be differently affected.

Prenatal imaging revealed skeletal malformations in a male Pomeranian foetus that was delivered stillborn. The cadaver was examined at the University Teaching Hospital, Faculty of Veterinary Medicine. Female littermate was born viable and developed normally. Despite detectable cardiac activity prenatally, the affected foetus showed marked neurocranial deformities and absence of multiple vertebral and rib structures. Postmortal CT confirmed normal cervical vertebrae and three thoracic vertebrae, with complete agenesis of all more caudal vertebral segments. The first two rib pairs were normally formed, the rest were absent. Postmortem examination revealed an open frontal meningocele (3 mm), complete cleft palate (palatoschisis), macroglossia (tongue 29 mm), and an umbilical hernia containing intestines. The kidneys were fused in a horseshoe configuration at the cranial poles, and lumbosacral agenesis was present. Lungs, liver, spleen, and kidneys were congested. The combination of meningocele, cleft palate, macroglossia, and lumbosacral agenesis indicates early embryonic disruption of neural tube development, while horseshoe kidneys and umbilical hernia suggest a generalized developmental disorder. Although similar anomalies have been sporadically reported in toy breeds, the severity and combination observed here are extremely rare. The normal female littermate suggests a likely spontaneous developmental error, though a genetic predisposition cannot be excluded.

This case highlights the value of integrated postmortem, imaging, and histopathological analyses for understanding neonatal mortality and congenital malformations in Pomeranians.

Keywords: Pomeranian; congenital malformations; meningocele; cleft palate; macroglossia; vertebral agenesis; horseshoe kidney

CRANIOMANDIBULAR OSTEOPATHY IN TWO ALPINE DACHSBRACKS – A CASE STUDY

Iva Sulić^{1*}, Ana Javor², Mirta Vučković³, Barbara Mratović², Anita Kraljević², Zoran Vrbanac², Hrvoje Capak²

¹PhD student, Faculty of Veterinary Medicine University of Zagreb, Zagreb, Croatia

²Department of Radiology, Ultrasound Diagnostic and Physical Therapy, Faculty of Veterinary Medicine University of Zagreb, Zagreb, Croatia

³Clinic for Surgery, Orthopedics and Ophthalmology, Faculty of Veterinary Medicine University of Zagreb, Zagreb, Croatia

*corresponding author: Iva Sulić, isulic@vef.unizg.hr

Craniomandibular osteopathy (CMO) is a rare, proliferative, self-limiting bone disorder characterised by abnormal bone growth that primarily affects young dogs of terrier breeds. Typically affected areas include the mandibular rami, tympanic bullae, occipital and parietal bones, temporomandibular joints, and zygomatic arches. CMO is inherited in an autosomal dominant manner with incomplete penetrance. To the best of the author's knowledge, this condition has not been previously reported in Alpine Dachsbracks (ADB).

At different times, two ADB dogs were referred to the Veterinary Teaching Hospital for diagnostic imaging and/or treatment. The dogs presented with different stages of progressive bilateral mandibular swelling, lip deformities, drooling, and difficulty eating solid food. In the first case, a 3-month-old male ADB, head radiographs revealed extensive, nearly symmetrical periosteal bone proliferations on both ramus mandible, along with additional osseous compaction of the frontal and occipital bones, indicating more advanced and widespread cranial involvement. Follow up was not provided. The second case involved an 8-month-old male ABD, although the owner reported problems lasting for at least 2 months. Radiography showed marked cortical thickening and irregular, ray-like periosteal proliferations affecting the right mandibular ramus, while the left ramus was unaffected. After medical treatment, the owner reported favorable recovery, without further complications. Due to its accessibility and diagnostic accuracy, radiography remains the primary modality for early detection and monitoring of CMO.

This case study describes two instances of CMO in purebred ADB, a breed in which the condition has not previously been documented. These findings suggest that CMO should be considered in the differential diagnosis of head bone disorders in various and atypical breeds, and also emphasise the need for further research into its prevalence and underlying causes.

Keywords: craniomandibular osteopathy; radiography; Alpine Dachsbrack

MAGNETIC RESONANCE IMAGING (MRI) SAFETY IN VETERINARY PATIENTS WITH RETAINED METALLIC PROJECTILES

Barbara Mratović^{1*}, Ana Javor¹, Sandro Gašpar², Branimir Škrilin¹, Hrvoje Capak¹

¹Department of Radiology, Ultrasound Diagnostic and Physical Therapy, Faculty of Veterinary Medicine University of Zagreb, Zagreb, Croatia

²PhD student, Children's Hospital Zagreb, Zagreb, Croatia

**corresponding author: Barbara Mratović, bmratovic@vef.unizg.hr*

Domestic and wild animals are often victims of intentional or accidental shootings, with stray bullets frequently detected during X-ray imaging. As magnetic resonance imaging (MRI) becomes more commonly used as a diagnostic method, there is a question of whether accidental bullets can cause issues such as heating, migration and tissue damage.

There is limited information about composition of firearm and air gun projectiles in Croatia, whereas in United States they do not contain steel and, therefore, are not ferromagnetic. Although the presence of a retained projectile is not always a contraindication for MRI, concerns arise due to uncertainty of their composition when casing is absent. Ballistic projectiles can be classified as ferromagnetic or non-ferromagnetic based on their appearance on X-rays or computed tomography (CT) scans, enabling patients with embedded non-ferromagnetic bullets to safely undergo MRI. The presence of steel bullets used in waterfowl hunting can be distinguished radiographically from lead bullets by its persistent round shape and lack of deformation on impact. On the contrary, a projectile that leaves a metallic debris trail from entry to final position or has been deformed is of composed of copper, copper-alloy, or lead with a partial jacketed configuration or represents lead shotgun bullets and does not pose a significant risk for imaging at 1.5 T MRI or lower, regardless of when the injury occurred. In human medicine, research indicates that the lead bullets do not exhibit interactions at 1.5T, 3T, or 7T MRI, respectively. Both ferromagnetic and non-ferromagnetic bullets do not significantly heat, even under extreme MRI conditions. However, the ferromagnetic bullets are likely unsafe for patients referred for MRI because of their potential to move in vivo. To develop fully safe MRI protocols, further research is needed to better understand the behaviour of retained bullets in veterinary patients, as most existing studies focus primarily on human medicine.

Keywords: Magnetic Resonance Imaging (MRI), retained metallic bullets, safety, animals

EFFECTS OF AGE AND BODY WEIGHT ON SEMEN QUALITY IN DOGS

Iva Lukrecia Lubina^{1*}, Ivan Tomić², Ivan Butković², Juraj Šavorić², Silvijo Vince², Martina Lojkić²

¹Veterinary Teaching Hospital, Faculty of Veterinary Medicine, University of Zagreb, Zagreb, Croatia

²Clinic for Obstetrics and Reproduction, Faculty of Veterinary Medicine, University of Zagreb, Zagreb, Croatia

**corresponding author: Iva Lukrecia Lubina, ivallubina@outlook.com*

Factors affecting semen quality are important for understanding canine reproductive physiology and predicting breeding outcomes. The objective of this study was to investigate the influence of body weight and age on semen quality parameters in dogs. The study included 47 dogs of 31 breeds presented at the Clinic for Obstetrics and Reproduction, Faculty of Veterinary Medicine, University of Zagreb, where semen was collected upon owners' request for evaluation or cryopreservation. Dogs were divided into four groups according to body weight (I: 1–15 kg, II: 15.1–30 kg, III: 30.1–40 kg, IV: >40 kg) and into two groups according to age (adult dogs <6 years, old dogs ≥6 years). Assessed parameters included ejaculate volume, sperm concentration, total sperm count, proportion of live sperm, and sperm morphology. Kinematic sperm parameters were analyzed using the CASA system (iSperm®). Body weight significantly affected semen volume, sperm concentration, and total sperm count. Semen volume in group I was significantly lower than groups II ($p < 0.01$), III ($p < 0.01$), and IV ($p < 0.001$). Total sperm count differed significantly between groups I and III ($p < 0.001$), I and IV ($p < 0.0001$), and II and IV ($p < 0.0001$). Sperm concentration differed only between groups II and IV ($p < 0.05$). Age showed a weak but significant negative correlation with sperm motility ($r = -0.34$, $p < 0.05$). In conclusion, body weight had a significant effect on semen quality parameters, especially ejaculate volume and total sperm count, which indicates its importance in semen evaluation. Age showed a weaker effect, though further research including a larger number of older dogs is needed to clarify its impact.

Keywords: dog, semen evaluation, body weight, age

EFFECT OF PASSIVE SMOKING ON SOME HEMATOLOGICAL PARAMETERS AND FATTY ACID COMPOSITION IN DOGS – PRELIMINARY STUDY

Sara Pavlović¹, Jasna Aladrović², Magdalena Oelsner¹, Branimira Špoljarić³, Ivan Butković³, Lana Pađen^{2*}

¹student, Faculty of Veterinary Medicine University of Zagreb, Zagreb, Croatia

²Department of Physiology and Radiobiology, Faculty of Veterinary Medicine University of Zagreb, Zagreb, Croatia

³Clinic for Reproduction and Obstetrics, Faculty of Veterinary Medicine University of Zagreb, Zagreb, Croatia

*corresponding author: Lana Pađen, lpaden@vef.unizg.hr

Cigarette smoke is complex mixture of chemicals produced by burning tobacco and additives. Domestic animals closely share a lifestyle with their owners and are potential victims of passive smoking. Literature regarding effect of passive smoking on hematological parameters and blood fatty acid (FA) composition in dogs is scarce, therefore, the aim of this study was to determine hematological parameters and blood FA composition in dogs from smoking (N=10, S) and non-smoking households (N=9; control, C).

Blood was collected as a part of the health monitoring program from dogs of different breeds, both genders mostly neutered, exposed to cigarette smoke for several hours a day. In this preliminary study, we did not take diet into consideration. Total number of blood cells, haemoglobin concentration haematocrit, erythrocytes and platelet indices were determined by haematology analyser using veterinary software. Differential leukocyte counts were determined from blood smears stained by the Pappenheim method. Total lipids of plasma were extracted, and composition of FA was determined by gas chromatography.

Plasma of C animals was dominated by polyunsaturated (PUFA, 43.14±3.31%), followed by saturated (SFA, 42.48±3.68%) and then monounsaturated FA (MUFA 14.39±1.09%). While plasma of S animals was dominated by SFA (42.92±2.47%), followed by PUFA (41.04±3.90%) and then MUFA (16.04±3.68%). Control animals had significantly higher C18:2n-6, PUFA and PUFA/SFA ratio (22.55±1.97% vs. 20.08±2.62%; 1.03±0.15% vs. 0.96±0.12%) compared to S animals. Omega 3 was higher in C compared to S animals (5.44±2.15% vs. 4.46±2.04%), but not significantly. Platelets were significantly higher in C animals (279±66x10⁹/L vs. 216±85 x10⁹/L) compared to S animals.

Lower essential FA (C18:2n-6) and higher platelets in S animals could suggest negative effect of cigarette smoke. Further research should focus on bigger sample size, differences in gender, erythrocytes FA composition and antioxidative status.

Keywords: passive smoking, dogs, haematology, fatty acid composition

ASSOCIATION BETWEEN EXPANSILE BONE LESIONS AND OLIGODONTIA IN DOGS AND CATS: A RETROSPECTIVE CT STUDY

Matea Gulić^{1}, Gabrijela Holjevac^{1**}, Ana Javor², Barbara Mratović², Mirta Vučković³, Iva Benvin⁴, Hrvoje Capak^{2**}**

¹student, Faculty of Veterinary Medicine, University of Zagreb, Zagreb, Croatia

²Department of Radiology, Ultrasound Diagnostic and Physical Therapy, Faculty of Veterinary Medicine, University of Zagreb, Zagreb, Croatia

³Clinic for Surgery, Orthopedics and Ophthalmology, Faculty of Veterinary Medicine, University of Zagreb, Zagreb, Croatia

⁴Department of Microbiology and Infectious Diseases with Clinic, Faculty of Veterinary Medicine, University of Zagreb, Zagreb, Croatia

**corresponding author: Hrvoje Capak hcapak@vef.unizg.hr*

***These authors contributed equally to this work.*

Oligodontia is a dental anomaly characterized by the absence of multiple teeth. Teeth may be missing due to congenital abnormalities (hypodontia) or acquired causes, including systemic infectious and parasitic diseases during the dentition period, periodontal disease, trauma, tooth extraction, or tooth loss in advanced age. There is a notable lack of data on oligodontia associated with expansile bone lesions.

Archived CT scans of dogs and cats at the Veterinary Teaching Hospital were reviewed. In total, 343 canine and 66 feline head CT scans were identified. Among all head CT scans, pathologies related to maxillary, mandibular, and dental abnormalities were recorded in 107 dogs (31%) and 24 cats (36%). Oligodontia was most frequently observed, occurring in 52 dogs (48.6%) and 16 cats (66.6%). Although the maxilla was more commonly affected than the mandible, oligodontia involving both jaws was present in 75% of dogs and 87.5% of cats. Causes of oligodontia were classified as expansile bone lesions and/or neoplasia, periodontal disease and oronasal fistulae, trauma or other etiologies. Classification was based on lesions identified within the same CT examination. For neoplastic lesions, histopathological confirmation was also used. The results showed that oligodontia associated with expansile bone lesions or neoplasia occurred in 21.2% of affected dogs and 18.8% of affected cats. Purebred dogs were classified by head type (mesocephalic, dolichocephalic, and brachycephalic), and contrary to expectations, mesocephalic dogs were most affected (42.3%). No breed predisposition was found due to the high proportion of mixed-breed dogs (>28%), although toy and small purebred dogs predominated; in cats, only one purebred animal (a Bengal) was identified.

Oligodontia was the most frequently identified maxillofacial and dental abnormality in this CT-based cohort of dogs and cats, with a notable proportion of cases associated with expansile bone lesions or neoplasia.

Keywords: Oligodontia; Computed Tomography (CT); Expansile Bone Lesions; Neoplasia; Dog; Cat

PRIMARY STABILIZATION AND EMERGENCY MANAGEMENT OF TWO CATS FOLLOWING SMOKE INHALATION

Klara Klašterka^{1*}, Iva Kuzman², Petra Dmitrović¹

¹Clinic for Surgery, Orthopedics and Ophthalmology, Faculty of Veterinary medicine, University of Zagreb, Zagreb, Croatia

²student, Faculty of Veterinary medicine, University of Zagreb, Zagreb, Croatia

**corresponding author: Klara Klašterka, kklasterka@vef.hr*

Smoke inhalation causes systemic hypoxia and airway inflammation due to thermal and chemical injury, as well as exposure to toxic gases such as carbon monoxide and hydrogen cyanide. Severity depends on the material burned, the temperature and the duration of exposure.

Two 6-month-old domestic cats were presented after an estimated two-hour exposure to smoke from a burning glass-ceramic plate. Both showed severe respiratory distress, vocalization, tachycardia, tachypnea, hypothermia and soot deposits on the tongue. Grey and dry mucous membranes, shortened capillary refill time, stridor, wheezes and an abdominal breathing pattern were noted. Mentation was reduced, and pupillary light reflexes were delayed.

Oxygen therapy was initiated immediately, followed by catheter placement and blood sampling. The male cat had unremarkable hematology, while the female had hemoconcentration. Both were markedly hyperkalemic, with elevated liver enzymes, pronounced metabolic acidosis and severe lactic acidemia. The female cat developed diarrhea and vomited black, tarry material. Mechanical ventilation was recommended, but the owners declined.

Therapy included fluid resuscitation with crystalloid boluses (5–10 mL/kg IV) and continuous infusion (6 mL/kg/h IV), oxygen supplementation (150 mL/kg/min), maropitant (1 mg/kg IV SID), saline nebulization every 4 hours, active warming and empiric ampicillin-sulbactam (22 mg/kg IV TID) due to inability to perform bronchoalveolar lavage. Buprenorphine (15 µg/kg IV q8h) was added after initial stabilization.

After four hours, the male cat showed rapid improvement in lactate, potassium and acid-base, while the female continued to deteriorate, and repeat sampling was not possible. By the next morning, the acid-base had further normalized, with thoracic radiographs confirming pulmonary opacity and edema consistent with smoke inhalation injury. He was discharged after three days. The female cat died approximately 8 hours after admission.

Keywords: smoke inhalation injury; feline; respiratory distress; hyperkalemia; metabolic acidosis; lactic acidemia.

EVALUATION OF COAGULATION PARAMETERS AS PROGNOSTIC INDICATORS IN CANINE HEATSTROKE

Ena Krajina¹, Lora Rosić¹, Damjan Gračner², Josipa Kuleš³, Maša Efendić^{2*}

¹student, Faculty of Veterinary Medicine, University of Zagreb, Zagreb, Croatia

²Clinic for Internal Diseases, Faculty of Veterinary Medicine, University of Zagreb, Zagreb, Croatia

³Department of Chemistry and Biochemistry, Faculty of Veterinary Medicine, University of Zagreb, Zagreb, Croatia

*corresponding author: Maša Efendić, mefendic@vef.unizg.hr

Due to climate change and rising temperatures, heatstroke in dogs is becoming increasingly common. It is a life-threatening emergency marked by loss of thermoregulation once body temperature exceeds 41 °C, leading to systemic inflammation, multi-organ failure, and potentially death. Key predictors of death include brachycephalic syndrome, obesity, hypoglycaemia, acute kidney injury (AKI), arrhythmias, seizures, and disseminated intravascular coagulation (DIC).

In heatstroke, DIC occurs due to activation of the coagulation cascade, triggered by direct thermal injury to tissues and the endothelium, potentially leading to consumption of platelets and coagulation factors. The aim of this study was to investigate the potential of DIC, as indicated by platelets, prothrombin time (PT), and activated partial thromboplastin time (aPTT), as a prognostic marker within the first 24 hours of patient admission.

The study included eight dogs with heatstroke admitted to the Clinic of the Veterinary Faculty, University of Zagreb. Blood samples were collected before any therapy, within 2 hours of symptom onset. Using the Vacutainer system, sodium-citrate tubes were used for PT and aPTT measurement with the QuickVet Analyzer (Zoetis, Denmark), and EDTA tubes for platelet analysis using the Horiba Scil Vet abc Plus (Viernheim, Njemačka). Two dogs showed prolonged PT and aPTT, with one surviving. Platelet counts were within reference ranges in all dogs except one that died and had severe thrombocytopenia.

In conclusion, Fisher's exact test found no significant association between coagulation abnormalities and survival (OR = 0.20, p = 0.464), though non-survivors tended to have higher values. Neither parameter showed a significant link with survival, but the small sample size and few non-survivors limit statistical power. Larger studies are needed to clarify potential associations.

Keywords: canine heatstroke, coagulation, disseminated intravascular coagulation (DIC), prognostic markers

QUALITATIVE DETECTION OF ANTIBODIES AGAINST PARVOVIROSIS AND DISTEMPER IN DOGS

Mija Curiš², Iva Zečević¹, Zrinka Štritof¹, Josipa Habuš¹, Suzana Hađina¹, Vladimir Stevanović¹, Iva Benvin¹, Ivona Ćorić¹, Gorana Miletić¹, Matko Perharić^{1*}

¹*Department of Microbiology and Infectious Diseases with Clinic, Faculty of Veterinary Medicine, University of Zagreb, Zagreb, Croatia*

²*Faculty of Veterinary Medicine, University of Zagreb, Zagreb, Croatia*

**corresponding author: Matko Perharić, mperharic@vef.unizg.hr*

Canine parvovirus and canine distemper are two highly contagious viral diseases that pose a significant threat to canine health worldwide. Both diseases are characterized by high morbidity and mortality rates, particularly in young dogs. Effective immunoprophylaxis, primarily through vaccination, remains the cornerstone of disease prevention and can protect dogs for several years. This study aimed to determine the duration of immunity in dogs that had previously been adequately vaccinated but had not received any booster vaccination for three years or more.

Plasma samples from 50 dogs admitted to the Clinic for Infectious Diseases, Faculty of Veterinary Medicine, were analyzed for antibodies to canine parvovirus and distemper using the Megacor FASTest[®] CDV-CPV Ab commercial test kit. Statistical analysis was performed using the chi-square test to compare group results. P-values <0.01 and <0.05 were considered statistically significant.

Among the group of dogs that had not received vaccination boosters for three to five years, 52.38% had a protective antibody titre against parvovirus. In contrast, within the group of dogs that had not been vaccinated for five or more years, only 41.37% retained a protective titre against parvovirus. Regarding immunity to canine distemper, 66.66% of dogs in the three-to-five-year post-vaccination group showed a protective antibody titre, while 68.96% of those unvaccinated for five years or longer maintained a protective titre against distemper. Statistical analysis revealed no significant difference in protective immunity levels between the two groups of dogs for either parvovirus or canine distemper. Furthermore, neither gender nor breed was associated with the level of protective immunity against these diseases.

The findings of this study suggest that assessing protective immunity within three years of the last vaccination is strongly advisable to ensure timely immunoprophylaxis against parvovirus and canine distemper.

Keywords: parvovirus, canine distemper, immunoprophylaxis, antibody titre, duration of immunity

PERIRENAL URINOMA ASSOCIATED WITH UNILATERAL HYDRONEPHROSIS IN A CAT

Iva Benvin^{1**}, Ana Javor^{2**}, Gorana Miletić¹, Branko Petričević³, Dražen Vnuk³, Suzana Hađina¹, Matko Perharić¹, Krešimir Martinković¹, Hrvoje Capak², Vladimir Stevanović¹, Iva Zečević¹, Ivona Ćorić¹, Josipa Habuš¹

¹*Department of Microbiology and Infectious Diseases with Clinic, Faculty of Veterinary Medicine University of Zagreb, Zagreb, Croatia*

²*Department of Radiology, Ultrasound Diagnostic and Physical Therapy, Faculty of Veterinary Medicine, University of Zagreb, Zagreb, Croatia*

³*Clinic for Surgery, Orthopedics and Ophthalmology, Faculty of Veterinary Medicine, University of Zagreb, Zagreb, Croatia*

**corresponding author: Iva Benvin, ibenvin@vef.unizg.hr*

***These authors contributed equally to this work.*

A urinoma is a localised collection of urine encapsulated by fibrous tissue due to urinary tract leakage. Perirenal urinomas in cats are rarely reported and may occur following trauma, surgical complications, or urinary tract obstruction.

A five-year-old female stray cat of unknown history, recently rescued in poor condition, was presented to the Veterinary Teaching Hospital. The cat exhibited clinical signs of upper respiratory tract disease. Blood analysis revealed marked leukocytosis with neutrophilia, non-regenerative anaemia, and hyperproteinaemia. A progressive FeLV infection was confirmed. Abdominal palpation indicated left-sided renomegaly, prompting thoracic and abdominal radiography and abdominal ultrasonography (US). Ultrasonography revealed a perirenal cystic structure adjacent to the left kidney, containing anechoic fluid and associated with unilateral hydronephrosis, with surrounding hyperechoic perirenal fat. US-guided fine-needle aspiration of the cystic fluid was performed. Bacterial culture and PCR testing for *Mycoplasma* spp. were negative, and cytology revealed neutrophilic inflammation of unknown aetiology. Treatment included fluid therapy, ampicillin, marbofloxacin, and supportive care. To further characterise the lesion, abdominal radiography was performed following intravenous administration of non-ionic iodinated contrast medium (Iohexol, Omnipaque®; 1.5 mL/kg). The cystic structure showed increased radiopacity post-contrast, indicating communication with the urinary tract and supporting a diagnosis of a perirenal cyst consistent with urinoma. Based on these findings, a left nephrectomy with omentalisation was performed, after which haematological parameters normalised and renal profile remained stable over six months.

Contrast radiography was essential for distinguishing a true urinoma from other perirenal fluid accumulations. Timely surgical treatment in cats with perirenal urinoma and unilateral hydronephrosis is crucial for full recovery.

Keywords: cat, perirenal urinoma, hydronephrosis, contrast radiography, nephrectomy

SECONDARY NUTRITIONAL HYPERPARATHYROIDISM IN A KITTEN – A CASE REPORT

Petar Krolo¹, Lucija Jeremić², Maša Efendić*²

¹PhD student, Faculty of Veterinary Medicine, University of Zagreb, Zagreb, Croatia

²Clinic for Internal Diseases, Faculty of Veterinary Medicine, University of Zagreb, Zagreb, Croatia

**corresponding author: Maša Efendić, mefendic@vef.hr*

Hyperparathyroidism is an endocrine disorder characterised by elevated secretion of parathyroid hormone (PTH), a key regulator of calcium and phosphorus homeostasis. Secondary hyperparathyroidism (SHP) is often classified as renal or nutritional, with the latter resulting from an unbalanced diet low in calcium or high in phosphorus, disrupting the recommended 1:1 Ca:P ratio in kittens. A six-week-old kitten was admitted to the Veterinary Faculty with lameness in the forelimbs and hindlimbs and unclear dietary history. Clinical examination revealed stunted growth and bilateral deformity of the fore and hind extremities.

The diagnostic procedure was significantly limited by the owner's financial constraints. Initial diagnostics included radiography of the chest, abdomen, and extremities. Blood was collected only for PTH concentration determination. Initial radiological findings confirmed severe generalised osteoporosis and suspected multiple pathological fractures. The diagnosis was confirmed by an elevated serum PTH concentration of 6.42 pmol/L, compared to the upper reference value of 2.5 pmol/L.

Treatment involved introducing balanced commercial kitten food and calcium/phosphorus supplementation with a ratio of 1.3:1, as the ideal 1:1 product was unavailable. After eight weeks, follow-up blood results showed a balanced 1:1 Ca:P ratio, and follow-up radiological findings showed no signs of osteoporosis.

This case highlights the role of PTH as a compensatory mechanism, where elevated PTH promotes extensive calcium resorption from bone, explaining the severe generalised osteoporosis with pathological fractures and possible compensation of serum calcium levels, which leads to secondary nutritional hyperparathyroidism. The successful resolution of the metabolic disorder through nutritional correction, despite the initial severe clinical and radiological changes, underscores the crucial importance of a proper Ca:P ratio, ideally 1:1, in kitten diets.

Keywords: metabolic disorder, kitten, secondary hyperparathyroidism, osteoporosis

SEPTIC HEMOPERITONEUM CAUSED BY AIR RIFLE PROJECTILE INJURY IN A DOG: CLINICAL AND SURGICAL MANAGEMENT

Iva Kuzman^{1*}, Karlo Tanhofer², Mirna Abaffy Kirin², Maša Efendić³, Petra Dmitrović²

¹Student, Faculty of Veterinary medicine, University of Zagreb, Zagreb, Croatia

²Clinic for Surgery, Orthopedics and Ophthalmology, Faculty of Veterinary medicine, University of Zagreb, Zagreb, Croatia

³Clinic for Internal Diseases, Faculty of Veterinary medicine, University of Zagreb, Zagreb, Croatia

*corresponding author: Iva Kuzman, ikuzman@vef.hr

A nine-year-old male Hungarian Vizsla was presented for suspected traumatic injury with a 1 cm wound on the right lateral abdomen, tachycardia, and tacky mucous membranes. Bloodwork revealed mild hypokalemia. Thoracic and abdominal radiographs identified a metallic-density foreign body consistent with an air rifle pellet near the left kidney, along with abdominal effusion. Abdominocentesis showed elevated lactate and decreased glucose levels, and a higher packed cell volume than in peripheral blood, confirming septic hemoperitoneum.

Primary stabilization included crystalloid boluses (10mL/kg/15mins IV) and continuous rate infusion (4 mL/kg/h IV), maropitant (1 mg/kg IV), and methadone (0.2 mg/kg IV). During stabilization, the packed cell volume decreased. Exploratory laparotomy under inhalant anesthesia revealed approximately 1200 mL of sanguineous effusion, mild subcapsular hemorrhage of the right kidney, capsular disruption of the left kidney, and jejunal perforation. A left-sided nephrectomy was performed to remove the damaged kidney, as well as jejunal resection with end-to-end anastomosis. Significant intraoperative hemorrhage required packed red blood cells and fresh frozen plasma transfusions, and norepinephrine infusion for blood pressure support. A 4.5 mm (.177 caliber) diablo pellet was retrieved from the cortex of the left kidney.

Postoperative monitoring included urine output, serum biochemistry (urea, creatinine, SDMA), and urinalysis. Culture sampled from the urinary catheter tip tested positive for multi-resistant *Pseudomonas oleovorans*, guiding continued antimicrobial therapy. The dog recovered uneventfully and was discharged six days later with stable hematologic and biochemical values. Such severe air-rifle-related injuries are uncommon and necessitate for comprehensive diagnostic evaluation and clinical assessment due to the wide range of potential trauma.

Keywords: air rifle, septic hemoperitoneum, penetrating abdominal trauma, kidney injury, jejunal perforation, canine

ERYTHROID MYELODYSPLASTIC SYNDROME PROGRESSING TO SUSPECTED ACUTE MYELOBLASTIC LEUKEMIA IN A MAINE COON CAT

Magdalena Bogović^{1*}, Katarina Marjanović¹, Elizabeta Pongrac¹, Marin Torti¹, Martina Crnogaj¹

¹*Clinic for Internal Diseases, Faculty of Veterinary Medicine, University of Zagreb, Croatia*

**corresponding author: Magdalena Bogović, mbogovic@vef.unizg.hr*

Myelodysplastic syndrome (MDS) of erythroid origin in cats is an uncommon clonal hematopoietic disorder characterized by marked erythroid dysplasia, ineffective erythropoiesis, and progressive cytopenias. Progression to leukemia is relatively common, especially in FeLV-positive cats, emphasizing the need for careful hematologic monitoring.

A 2-year-old neutered male Maine Coon was presented for a second opinion after one week of lethargy and hyporexia. On admission the cat was laterally recumbent, febrile, and pale. CBC revealed severe non-regenerative anemia and thrombocytopenia with immature circulating cells, basket cells, macrothrombocytes, and lymphoglandular bodies. Serum biochemistry showed increased urea, total bilirubin, AST, ALT, and CK, with decreased potassium. The IDEXX SNAP FIV/FeLV Combo test was negative.

Thoracic radiographs and abdominal ultrasound identified hepatosplenomegaly and generalized lymphadenopathy. Cytology of the jejunal lymph nodes and spleen suggested erythroid leukemia or erythroid-origin MDS. Bone-marrow biopsy confirmed erythroid-lineage MDS, and FeLV PCR on marrow was positive.

The cat received stabilization, including RBC transfusion, followed by cytarabine chemotherapy (100 mg/m² SC for four days with two additional weekly cycles). After one-month, clinical signs worsened, and CBC revealed marked leukocytosis with numerous immature cells and basket cells, consistent with progression to acute myeloblastic leukemia (AML).

Given the rapid deterioration and poor prognosis, treatment was discontinued at the owners' request. The cat was euthanized one week later, 53 days after initial presentation.

This case illustrates the aggressive biological behaviour of erythroid-origin MDS in FeLV-positive cats, emphasizes the diagnostic importance of bone marrow examination and molecular testing, and highlights the substantial risk of progression to AML despite early intervention, noting that therapeutic responses are variable.

Keywords: Maine Coon, anemia, bone marrow, MDS, cytarabine, AML

MULTIPLE MYELOMA IN A STAFFORDSHIRE TERRIER: A CASE REPORT

Magdalena Bogović^{1*}, Katarina Marjanović¹, Elizabeta Pongrac¹, Filip Kajin¹, Iva Šmit¹, Marin Torti¹

¹Clinic for Internal Diseases, Faculty of Veterinary Medicine, University of Zagreb, Zagreb, Croatia

**corresponding author: Magdalena Bogović, mbogovic@vef.unizg.hr*

Multiple myeloma in dogs is a malignant plasma-cell disorder characterized by clonal proliferation of plasma cells within the bone marrow and other organs, leading to hyperglobulinemia, cytopenias, osteolytic lesions, and renal dysfunction. Although response to chemotherapy is often favorable, prognosis varies with disease chronicity and extent of organ involvement at the time of diagnosis.

A 12-year-old male neutered Staffordshire Terrier was presented for a second opinion after several months of lethargy and anorexia and a six-month history of progressive splenomegaly. On admission, the dog was depressed, with icteric, tacky mucous membranes and a prolonged capillary refill time. Complete blood count showed mild anemia and thrombocytopenia. Serum biochemistry demonstrated azotemia, marked hyperproteinemia with hypoalbuminemia, increased liver enzyme and DGGR-lipase activities. Acid–base analysis revealed hyperlactatemia.

Abdominal ultrasonography identified severe splenomegaly with markedly inhomogeneous parenchyma. Fine-needle aspiration of the spleen showed cytologic features consistent with plasma-cell neoplasia. Serum protein electrophoresis confirmed a monoclonal gammopathy, and urinalysis detected Bence–Jones proteins, supporting a diagnosis of multiple myeloma with significant extramedullary involvement.

Chemotherapy with melphalan and prednisolone was initiated the following day. Despite treatment, the dog deteriorated rapidly and died two days later. Although published survival times for dogs receiving melphalan-based protocols range from approximately 1.5 to 3 years, this patient likely had advanced, long-standing disease given the chronicity of clinical signs and prolonged splenomegaly prior to referral.

This case highlights the variable clinical course and prognosis of canine multiple myeloma and underscores the value of early diagnostic evaluation and staging to optimize therapeutic benefit.

Keywords: splenomegaly, monoclonal gammopathy, Bence-Jones, multiple myeloma

CT-ASSISTED DIAGNOSIS AND SURGICAL REPAIR OF A TRAUMATIC ORONASAL DEFECT IN A DOG- A CASE REPORT

Mirta Paić Radovniković¹, Marija Mamić², Ana Javor³, Mirta Vučković^{2*}

¹Veterina Branimir d.o.o., Zagreb, Croatia

²Clinic for Surgery, Orthopaedics and Ophthalmology, Faculty of Veterinary Medicine University of Zagreb, Croatia

³Department of Radiology, Ultrasound Diagnostic and Physical Therapy, Faculty of Veterinary Medicine, University of Zagreb, Croatia

**corresponding author: Mirta Vučković, mirta.vuckovic@vef.unizg.hr*

Traumatic palatal injuries in dogs may result in oronasal communication, leading to chronic infection, nasal discharge, and feeding difficulties. Appropriate diagnosis and surgical management are essential for successful outcomes.

A 10-year-old male mixed-breed dog was presented with a one-year history of malodorous nasal discharge following maxillofacial trauma caused by a vehicular accident. Despite three previous surgical procedures and intermittent empirical antibiotic therapy, no clinical improvement was achieved. Clinical examination revealed painful maxillary palpation, oral and nasal discharge, and a centrally located hard palate defect at the level of the first molars, forming a 3 mm oronasal communication.

Computed tomography (CT) of the head was performed to evaluate the lesion and revealed a median caudal hard palate defect (2.5 × 1.8 cm) extending rostrally to the last maxillary premolars, with palatine bone deformation, thinning, and associated destruction of the nasal turbinates. Mild soft-tissue attenuation was present in the left nasal passage. Microbiological sampling from the defect identified *Escherichia coli* susceptible to amoxicillin–clavulanic acid.

Surgical reconstruction was performed using a transposition flap, followed by targeted antimicrobial therapy, nasogastric feeding, and analgesia. Follow-up examinations confirmed complete closure of the defect and satisfactory healing.

This case highlights that clinical improvement in chronic and complicated oronasal defects may be achieved only after a structured, multimodal diagnostic and therapeutic approach, combining advanced CT-based surgical planning and targeted antimicrobial treatment following prolonged unsuccessful management.

Keywords: CT, dog, oro-nasal communication, palatal trauma, transposition flap

FOCUSED EXTRACORPOREAL SHOCKWAVE THERAPY AND PHOTOBIO-MODULATION IN THE REHABILITATION OF A DOG WITH BILATERAL SCAPULOHUMERAL OSTEOARTHRITIS: A CASE REPORT

Anita Kraljević^{1*}, Ivana Mustapić², Iva Matijević², Barbara Mratović¹, Jelena Adanić³, Ana Javor¹, Zoran Vrbanac¹

¹Department of Radiology, Ultrasound Diagnostic and Physical Therapy, Faculty of Veterinary Medicine, University of Zagreb, Zagreb, Croatia

²student, Faculty of Veterinary Medicine, University of Zagreb, Zagreb, Croatia

³Doctor of Veterinary Medicine, Zagreb, Zagreb, Croatia

*corresponding author: Anita Kraljević, akraljevic@vef.unizg.hr

Osteoarthritis (OA) is a common, chronic, and painful condition in dogs, typically managed with medication, physical rehabilitation, and weight control. Focused extracorporeal shockwave therapy (ESWT) and Class IV laser therapy, also known as photobiomodulation (PBM), are used to reduce pain, control inflammation, and support tissue regeneration.

A 13-year-old wire-haired German Pointer presented with bilateral forelimb lameness. Clinical and radiographic examinations confirmed bilateral scapulohumeral OA. The initial assessment revealed reduced shoulder joint range of motion, particularly in the right limb. The dog underwent a five-week rehabilitation protocol consisting of PBM administered twice weekly (9.5 W, 3:49 min, 2175.5 J) and focused ESWT once weekly (1000 pulses, 5 Hz, 0.172–0.23 mJ/mm²). Pain severity and functional impairment, as reported by the owner, were evaluated using the Canine Brief Pain Inventory (CBPI), providing structured and quantitative insights throughout the rehabilitation process.

Measurable improvements in flexion and extension were observed following ten therapy sessions. Right shoulder flexion improved from 65° to 55° and extension increased from 140° to 163°. Left shoulder flexion improved from 60° to 56°, with extension increasing from 163° to 164°. Weight-bearing distribution, assessed with a stance analyzer, initially revealed mild forelimb asymmetry. Subsequent measurements showed stable and balanced limb loading after the treatment period.

This case suggests that combining ESWT and PBM may benefit geriatric patients with osteoarthritis by reducing pain, improving mobility, and enhancing quality of life.

Keywords: ESWT, photobiomodulation, stance analyser, osteoarthritis

Acknowledgements

The authors thank and acknowledge Multi Radianc Medical for providing the MPACTVet device and Enovis for Companion Stance Analyzer; the companies had no role in study design, data collection, analysis, or interpretation.

FOLLOW YOUR GUT: INSIGHTS FROM SMALL ANIMAL GASTROINTESTINAL ENDOSCOPY

Lucija Jeremić¹, Elizabeta Pongrac¹, Martina Crnogaj¹, Petar Krolo², Ivana Kiš¹, Maša Efendić¹, Katarina Marjanović¹, Iva Šmit^{1*}

¹*Clinic for Internal Diseases, Faculty of Veterinary Medicine, University of Zagreb, Zagreb, Croatia*

²*PhD student, Faculty of Veterinary Medicine, University of Zagreb, Zagreb, Croatia*

**corresponding author: Iva Šmit, ismit@vef.unizg.hr*

Endoscopy of the gastrointestinal tract is an essential diagnostic and therapeutic modality in small animal veterinary medicine. This retrospective study aimed to analyze the most common indications, findings, complications, and outcomes of endoscopic procedures in domestic carnivores over one-year period (1 November 2024 – 1 November 2025) at the Clinic for Internal Medicine, Faculty of Veterinary Medicine, University of Zagreb.

A total of 74 endoscopies were performed: dogs comprised the majority (64/74; 86.5%), followed by cats (9/74; 12.2%) and one ferret (1/74; 1.3%). Among dogs, mixed-breed animals were most represented (28.1%), whereas the most common breed among cats was the European Shorthair (66.7%). In dogs, a moderate male predominance was observed (56.3%), while females predominated in feline cohort (55.6%).

The most frequent indications for endoscopy in dogs were suspicion of a foreign body (48.4%), whereas in cats chronic gastrointestinal signs predominated (77.8%). Foreign bodies were found in 24 dogs and 1 cat, with successful removal in 83% of dogs and 100% of cats. The most common foreign body types included plastic items (29.17%), bones (20.83%), metallic objects (16.67%), and balls (12.5%).

Biopsies were performed in 39.1% of dogs and 55.6% of cats, most commonly revealing inflammatory changes. Complications were rare, occurring in 10.9% of dogs and 22.2% of cats, with hemorrhage being the most frequent. The overall outcome was favorable in most animals, with a few euthanized due to poor clinical condition or an unfavorable prognosis.

These findings provide valuable insight into the frequency, indications, and outcomes of endoscopic procedures in small animals, highlighting the importance of endoscopy as both a diagnostic and therapeutic tool.

Keywords: *endoscopy, foreign bodies, biopsy, inflammation, neoplasia*

CONSIDERING TAURINE-RESPONSIVE MYOCARDIAL DYSFUNCTION DESPITE NORMAL BLOOD TAURINE: A CASE REPORT IN A WEIMARANER

Maša Efendić, Marin Torti*

Clinic for Internal Diseases, Faculty of Veterinary Medicine, University of Zagreb, Zagreb, Croatia

**corresponding author: Marin Torti, mtorti@vef.unizg.hr*

Taurine plays an important role in myocardial function, and taurine-responsive cardiomyopathy has been described in several dog breeds. However, the etiology is multifactorial and blood taurine concentrations may not reliably reflect myocardial taurine status.

A healthy 4-year-old female Weimaraner (32.1 kg), underwent cardiologic screening for breeding certification and was diagnosed with mild systolic dysfunction based on volumetric echocardiographic measurements. The modified Simpson method showed a left ventricular systolic volume (LVSV) of 56.6 ml, exceeding published reference values for dogs, and the E-point to septal separation (EPSS) was increased to 0.8 cm. Routine laboratory testing, including blood taurine concentration, cardiac troponin I, and vector-borne disease screening, returned results within normal limits. A Holter-ECG and thyroid panel were not performed; however, no clinical signs suggestive of hypothyroidism and no arrhythmias were detected during the exam.

Despite normal blood taurine concentration, empirical taurine supplementation (1500 mg PO BID) was initiated due to the ongoing debate regarding the sensitivity of blood taurine measurements, the possibility of myocardial depletion without detectable deficiency, and documented clinical reversibility in some cases of nutritional cardiomyopathy. No additional cardiac medications were given, and the dog's diet remained unchanged. After 3 months, echocardiography showed improvement with LVSV decreasing to 41.6 ml and EPSS to 0.5 cm.

This case shows a temporal association between taurine supplementation and improved systolic function; however, causation cannot be confirmed. It highlights that taurine-responsive myocardial dysfunction may still be considered even when blood taurine concentrations fall within reference intervals, as circulating values may not reflect myocardial status.

Keywords: nutritional cardiomyopathy, taurine supplementation, systolic dysfunction, Weimaraner, echocardiography

MANAGEMENT OF FELINE STOMATITIS USING CLASS 4 LASER PHOTOBIO-MODULATION

Manar Loay Aly Mohamed Aly¹, Anita Kraljević², Ana Javor², Barbara Mratović², Hrvoje Capak², Iva Zečević³, Zoran Vrbanac²

¹*Evidensia Specialisthästsjukhuset, Helsingborg, Sweden*

²*Department of Radiology, Ultrasound Diagnostic and Physical Therapy, Faculty of Veterinary Medicine, University of Zagreb, Zagreb, Croatia*

³*Department of Microbiology and Infectious diseases with Clinic, Faculty of Veterinary Medicine, University of Zagreb, Zagreb, Croatia*

**corresponding author: Manar Loay Aly Mohamed Aly, manarloay@hotmail.com*

Feline stomatitis, also known as Feline Chronic Gingivostomatitis (FCGS), is a painful oral inflammatory condition that significantly compromises feline welfare and quality of life. Conventional management strategies, including full-mouth dental extractions and long-term immunosuppressive therapy, are often invasive, of variable efficacy, and associated with potential side effects.

This study aimed to evaluate Class 4 laser photobiomodulation as a non-invasive alternative for FCGS management. Seven client-owned cats (mean age 5.7 years; mean body weight 4.0 kg) with chronic oral inflammation were treated using a standardized protocol. All cats received three weekly extraoral applications of Class 4 laser therapy. Treatment parameters were carefully controlled (power output: 3.0 W, continuous wave, total energy delivered: 441.0 J). Clinical responses were assessed using paired owner questionnaires evaluating pain, appetite, salivation, and visible oral lesions. In three cases, photographic documentation was used to visually monitor lesion regression and mucosal healing.

Clinical improvement was quantified as a relative improvement percentage, normalizing each cat's progress toward the maximum possible clinical score. Results demonstrated consistent improvement, ranging from 10.0% to 70.0% (mean 27.9%). No adverse effects were observed. All treatments were well tolerated, with no need for sedation or concurrent medications. Future prospective studies should include a larger sample size and incorporate objective clinical assessments to validate these preliminary findings.

Nevertheless, these preliminary results suggest that Class 4 laser photobiomodulation is a safe, effective, and minimally stressful option for managing feline stomatitis, particularly in cases unresponsive to conventional therapy.

Keywords: Feline stomatitis, Feline Chronic Gingivostomatitis, Photobiomodulation, Class 4 laser, Oral inflammation

ECTOPIC PAROTID GLAND TISSUE IN THE DOG: A CASE REPORT

Magdalena Kolenc^{1*}, Noah Huljev², Nikolina Škvorc¹, Martina Đuras¹, Tajana Trbojević Vukičević¹, Kim Korpes¹

¹Department of Anatomy, Histology and Embryology, Faculty of Veterinary Medicine University of Zagreb, Zagreb, Croatia

²student, Faculty of Veterinary Medicine University of Zagreb, Zagreb, Croatia

**corresponding author: Magdalena Kolenc, mkolenc@vef.unizg.hr*

The parotid gland (glandula parotis) is a serous, tubuloacinar salivary gland located in the parotid region just ventral to the auricle. In dogs, its duct (ductus parotideus) crosses the lateral side of the masseter muscle and opens on the parotid papilla on the cheek inside the vestibulum of the oral cavity. During dissection practicals in the anatomy course (academic year 2025/2026) at the *Faculty of Veterinary Medicine University of Zagreb*, a structure of unknown origin was observed attached to the left parotid duct in an adult medium-sized dog. The structure was oval-shaped (length: 1.41 cm) and macroscopically resembled glandular tissue, being lobulated and dark pink in colour. It was adjacent to the parotid duct at the rostral edge of the masseter muscle. The structure and parotid duct were sampled, fixed in 10% neutral buffered formalin, and subjected to histological analysis. Microscopically, the tissue was surrounded by a connective tissue capsule with septa dividing it into lobules. Each lobule was composed of serous acini formed by pyramidal cells, accompanied by efferent duct system. Based on anatomical and histological characteristics, the tissue was identified as ectopic parotid gland tissue. This refers to the presence of glandular tissue located outside its normal anatomical position. In dogs, ectopic parotid tissue is rare and may occur in the regions of the neck, pharynx, around the ear, and along the parotid duct. Clinically, it most often presents as a firm, small, nodular mass. Most dogs show no symptoms unless the ectopic tissue causes obstruction of salivary drainage, develops inflammation (*sialadenitis*), forms a cyst (*sialocele* or *mucocele*), or is misinterpreted as a neoplasm. In many cases, such tissue is discovered incidentally during diagnostic imaging or surgery performed for an unrelated reason. This case highlights the importance of considering anatomical variation of salivary tissue in clinical work.

Keywords: parotid gland, ectopic tissue, dog

RELATIONSHIP BETWEEN CREATININE CONCENTRATION AND CHANGES IN SERUM METABOLOME IN BITCHES WITH PYOMETRA

Dora Ivšić Škoda^{1*}, Branimira Špoljarić², Martina Lojkić², Iva Getz², Nikica Prvanović Babić², Josipa Kuleš³, Renata Barić Rafaj³, Ivana Rubić⁴, Dina Rešetar Maslov⁴, Vladimir Mrljak¹

¹*Clinic for Internal Diseases, Faculty of Veterinary Medicine, University of Zagreb, Zagreb, Croatia*

²*Clinic for Reproduction and Obstetrics, Faculty of Veterinary Medicine, University of Zagreb, Zagreb, Croatia*

³*Department of Chemistry and Biochemistry, Faculty of Veterinary Medicine, University of Zagreb, Zagreb, Croatia*

⁴*Laboratory of Proteomics, Faculty of Veterinary Medicine, University of Zagreb, Zagreb, Croatia*

**corresponding author: Dora Ivšić Škoda, divsicskoda@vef.unizg.hr*

Pyometra is a common inflammatory disease of the uterus in bitches that can progress to sepsis and multiple organ dysfunction. An increase in serum creatinine in dogs by 26.4 $\mu\text{mol/L}$ over 48 hours indicates the development of acute kidney injury. However, in sepsis, alterations in creatinine metabolism may result in undetected kidney injury. The aim was to identify metabolomic changes associated with different serum creatinine (sCr) concentrations in bitches with pyometra.

The analysis was performed on the serum of spontaneously pyometra-infected bitches (N=19; sCr<140 $\mu\text{mol/L}$) using a non-targeted metabolomic method with a Dionex Ultimate 3000 UHPLC system coupled to a Q Exactive Plus Orbitrap mass spectrometer. One group included bitches with sCr<70 $\mu\text{mol/L}$ (N=8), and the other group included bitches with sCr \geq 70 $\mu\text{mol/L}$ (N=11). Metabolomic data were processed using the online statistical programme MetaboAnalyst 6.0.

Statistical analysis of the metabolomic data from the serum of bitches with pyometra revealed a significant change in the relative intensities of 24 peaks (Student's t-test, $p<0.05$; Fold change analysis, $\text{FC}\geq 1.5$). In the group of bitches with pyometra and sCr \geq 70 $\mu\text{mol/L}$, the metabolites 4-trimethylammonium-butanoate, L-phenylalanine and creatinine were statistically significantly changed.

4-Trimethylammonium-butanoate is a precursor of L-carnitine, which is involved in the transport of activated fatty acids through the mitochondrial membrane in mitochondrial β -oxidation. Phenylalanine concentrations may be elevated in sepsis, probably as a result of skeletal muscle catabolism. Similar results have been observed in kidney and liver failure.

The results indicate mechanisms that are activated in the early phase of kidney function deterioration in pyometra. Metabolomic changes identified in the serum of bitches with pyometra that accompany the increase in creatinine concentration indicate the development of inflammation and disturbances in cell energy metabolism.

Keywords: metabolomics, creatinine, dog, pyometra

ACID-BASE STATUS PARAMETERS OF HEPARINIZED VENOUS DOG BLOOD DURING STORAGE AT ROOM TEMPERATURE

Antonia Žuvela^{1*}, Dora Ivšić Škoda¹, Vlasta Đurić¹, Jasna Aladrović², Blanka Beer Ljubić¹

¹Clinic for Internal Diseases, Faculty of Veterinary Medicine, University of Zagreb, Zagreb, Croatia

²Department of Physiology and Radiobiology, Faculty of Veterinary Medicine, University of Zagreb, Zagreb, Croatia

**corresponding author: Antonia Žuvela, azuvela@vef.hr*

Acid-base status (ABS) is a laboratory test for assessing the balance between acids and bases in the body and provides insight into metabolic and respiratory disorders in humans and animals. Arterial, capillary and venous blood can be used for ABS analysis. Erroneous blood storage leads to inaccurate results and subsequently misinterpretation. The aim of the study was to investigate how venous blood storage at room temperature affect the values of ABS parameters. The study was conducted on blood samples from 29 dogs, samples were taken from the cephalic vein using pre-heparinized syringes (Sanguis Counting, Germany) under anaerobic conditions. Analyses were performed in four consecutive measurements: within 10 min after blood collection and 10, 20 and 40 minutes after initial measurement. Analyses were performed on a GEM 3500 Premier analyzer (IL, USA), and values for potassium, sodium, lactate, glucose, ionized calcium, pH, hematocrit, pCO₂ (partial CO₂ pressure) and pO₂ (partial O₂ pressure) were determined. Storage of heparinized venous blood from dogs at room temperature resulted in a significant increase in pO₂ 40 minutes after initial measurement. Lactate concentration showed trend of increase while pH showed trend of decrease during storage but without significance (P=0.068; P=0.097, respectively). Potassium, sodium, glucose, ionized calcium concentrations, hematocrit, and pCO₂ values were not affected by storage. The changes in ABS parameters observed during room temperature storage of heparinized venous blood from dogs indicate anaerobic metabolism and release of oxygen from erythrocytes due to pH decrease. Given the activity of cells in whole blood, it is necessary to deliver the blood to the laboratory as soon as possible and perform the analysis immediately.

Keywords: heparinized venous blood, dog, acid-base status, room temperature storage

INFLUENCE OF SHORT-TERM SERUM STORAGE IN SEPARATE TUBE ON ENZYMES ACTIVITY IN DOGS

Katarina Šarotar¹, Antonia Žuvela², Dora Ivšić Škoda², Vlasta Đurić², Jasna Aladrović³, Blanka Beer Ljubić²

¹Student, Faculty of Veterinary Medicine, University of Zagreb, Ul. Vjekoslava Heinzela 55, Zagreb, Croatia

²Clinic for Internal Diseases, Faculty of Veterinary Medicine, University of Zagreb, Ul. Vjekoslava Heinzela 55, Zagreb, Croatia

³Department of Physiology and Radiobiology, Faculty of Veterinary Medicine, University of Zagreb, Ul. Vjekoslava Heinzela 55, Zagreb, Croatia

Preanalytical factors, such as storage conditions and tube type, can influence the reliability of biochemical test results. Proper sample handling is therefore essential to ensure the validity of laboratory analyses. The aim of this study was to evaluate the effect of 12-hour serum storage on gel in collection tubes and on the concentrations of diagnostically important enzymes in canine serum. Blood samples were collected from the cephalic vein of ten dogs into serum separator tubes. Following centrifugation at 1600g for 10 minutes, analyses of aspartate aminotransferase (AST), alanine aminotransferase (ALT), gamma-glutamyl transferase (GGT), alkaline phosphatase (ALP), creatine kinase (CK) and lactate dehydrogenase (LDH) were performed using the Abbott Architect Plus c4000 biochemical analyzer. Subsequently, 200 µL of serum was returned to the original gel tubes and another 200 µL transferred into plain plastic tubes. After 12 hours of storage at room temperature, the analyzes were repeated. Statistical comparison of the initial and 12-hour results revealed no significant differences in any of the tested enzymes. These findings indicate that short-term storage of canine serum samples on gel at room temperature does not significantly affect enzymes activity. The results are consistent with the manufacturer's specifications for human samples and confirm the stability of the tested biochemical parameters under the described conditions.

Keywords: canine serum, serum separate tube, storage condition, enzymes activity

DOES SHORT-TERM CANINE SERUM STORAGE ON GEL AFFECT CONCENTRATION OF DIAGNOSTICALLY IMPORTANT SUBSTRATES?

Teuta Blažić^{1*}, Antonia Žuvela², Dora Ivšić Škoda², Vlasta Đurić², Jasna Aladrović³, Blanka Beer Ljubić²

¹Student, Faculty of Veterinary Medicine, University of Zagreb, Heizelova 55, Croatia

²Clinic for Internal Diseases, Faculty of Veterinary Medicine, University of Zagreb, Croatia

³Department of Physiology and Radiobiology, Faculty of Veterinary Medicine, University of Zagreb, Croatia

**corresponding author: Teuta Blažić, teutablazic@gmail.com*

Storage is a very important aspect of preanalytics and a potential source of error. The manufacturer of biochemical analyzers and reagents guarantees the validity of results obtained when their instructions are being followed. It is recommended for each laboratory to validate whether these instructions are applicable to their specific samples. The purpose of this study was to test how 12-hour storage of dog serum samples in serum separator tubes affects the results of diagnostically important substrates. Blood samples from ten dogs were collected from cephalic vein into gel tubes. After centrifugation, serum samples were obtained. Analyses of urea, creatinine, total proteins, albumin, bilirubin, glucose, triglycerides and cholesterol were performed on a biochemical analyzer Abbott Architect Plus c4000. Following the initial measurements, 200 µL of each sample was returned to the original serum separator tubes used for blood collection and another 200 µL was transferred into clean plastic microtubes. A second set of data was obtained after 12 hours of storage at room temperature. Statistical testing showed no significant differences between the initial and second results. Based on the results we can conclude that canine serum samples stored at room temperature for 12 hours as well as the presence or absence of gel in the sample do not alter the concentration levels of the tested substrates which is consistent with the manufacturer's instructions for human samples.

Keywords: canine serum, storage conditions, serum separator tube, biochemical parameters

EQUINE SESSION
ORAL PRESENTATIONS

PHYSEAL FRACTURE OF THE LATERAL EPICONDYLE OF THE HUMERUS IN A FOAL WITH TETANUS – A CASE REPORT

Katarina Miljak^{1*}, Jelena Gotić², Darko Grden², Petra Bratić², Matko Perharić³, Lidija Medven Zagradišnik⁴, Nika Brkljača Bottegaro¹

¹Clinic for Surgery, Orthopaedics and Ophthalmology, Faculty of Veterinary Medicine University of Zagreb, Zagreb, Croatia

²Internal Medicine, Faculty of Veterinary Medicine, University of Zagreb, Zagreb, Croatia

³Infectious Diseases, Faculty of Veterinary Medicine, University of Zagreb, Zagreb, Croatia

⁴Veterinary Pathology, Faculty of Veterinary Medicine, University of Zagreb, Zagreb, Croatia

**corresponding author: Katarina Miljak, kmiljak@vef.unizg.hr*

Humeral fractures are uncommon in foals and are usually a result of direct trauma. Clostridium tetani causes tetanus in foals, with the most common entry through the umbilicus. It occurs when mares are unvaccinated, no tetanus antitoxin is administered at birth, and navel hygiene is neglected. These lapses in preventive care allow the bacteria to multiply and produce toxins that lead to clinical disease.

This case report describes a 4-month-old WB foal which was admitted to the University Teaching Hospital with progressive generalised muscle stiffness, muscle spasms and third eyelid prolapse, consistent with tetanus. A ventricular septal defect was suspected based on the characteristic cardiac murmur detected on auscultation and was subsequently confirmed by ultrasonographic examination. Treatment included tetanus antitoxin, antibiotics, sedation, muscle relaxants, and supportive care. Although clinically stable for two weeks, the condition deteriorated, with worsening spasms leading to recumbency and inability to stand. After several days, marked swelling of the left forelimb was observed with further worsening of the clinical signs. Radiographic examination confirmed a physeal fracture of the lateral humeral epicondyle, presumed avulsion due to the intense tetanic muscle contractions of the whole extensor of carpi and digit muscle group, since there was no other evidence of trauma. Considering the severe neuromuscular impairment and fracture-related pain euthanasia on humane grounds was elected by the owner.

This is the first reported case of a humeral physeal fracture secondary to tetanus in a foal. It highlights that the extreme forces from tetanic spasms can cause growth-plate avulsion fractures, even in large bones. Clinicians treating tetanus should closely monitor recumbent foals for limb swelling, or crepitus, as fractures may develop. The case emphasizes the importance of routine preventative methods to protect from this entirely avoidable disease.

Keywords: foal, tetanus, physeal humeral fracture

PERSISTENT HYALOID ARTERY AND COLOBOMA IN A HORSE – A CASE REPORT

Katarina Miljak¹, Antea Rački², Nika Brkljača Bottegaro¹, Marija Mamić¹

¹*Clinic for Surgery, Orthopaedics and Ophthalmology, Faculty of Veterinary Medicine University of Zagreb, Zagreb, Croatia*

²*Veterinary clinic Klanjec, Klanjec Croatia*

**corresponding author: Katarina Miljak, kmiljak@vef.unizg.hr*

Persistent hyaloid artery and iris coloboma combined are not well-documented congenital ocular disorders in horses when compared with other species. Iris coloboma results from incomplete closure of the optic fissure, producing a characteristic alteration of the pupil shape. Persistent hyaloid artery represents a remnant of the vascular system that fails to regress in the first nine months.

A 9-year-old Warmblood mare was referred because of the presence of a white mass in the posterior segment of the left eye, which was suspected to be posterior lens luxation. Ophthalmic examination revealed a positive but slower menace response, direct and consensual pupillary light reflex and absent dazzle reflex in the left eye. The examination of the right eye revealed no abnormalities. Further examination of the left eye showed no abnormalities of the cornea and the anterior chamber. A typical iris coloboma at the 6 o'clock position was present, and the lens with nuclear cataract was found in its physiological position. On the posterior capsule of the lens at the 6 o'clock position, a focal white, non-transparent oval opacity was observed. The posterior segment of the eye could not be examined due to the presence of cataract and the described opacity. Intraocular pressure was within the normal range on both eyes. Ultrasound examination of both eyes was performed and showed an 8 x 7mm hyperechoic mass adjacent to the posterior capsule of the lens and the retina in the left eye. Doppler imaging demonstrated blood flow within the mass and its connection to the retina, consistent with a persistent hyaloid artery. This case illustrates that a persistent hyaloid artery, although rare in adult horses, can mimic posterior lens pathology and may be mistaken for lens luxation or other vitreous abnormalities. Recognition of this anomaly is important to avoid unnecessary interventions. Thorough ophthalmic and ultrasonographic examination, including Doppler assessment, is recommended for accurate diagnosis.

Keywords: iris coloboma, persistent hyaloid artery, congenital ocular disorder, ocular ultrasound

RUPTURE OF THE LONGUS CAPITIS MUSCLE IN SEVENTEN HORSES

Luka Špelić¹, Sonja Berger¹, Rosa Barsnick², Vicky Frisch¹

¹Clinical Center for Equine Health and Research, University of Veterinary Medicine, Veterinärplatz 1, Vienna, Austria

²Barsnick Equine Internal Medicine Emergency Critical Care, Kolbstrasse 21, Kirchheim unter Teck, Germany

**corresponding author: Luka Spelic, luka.spelic@vetmeduni.ac.at*

This case series describes seventeen horses diagnosed with a ruptured longus capitis muscle (LCM). Rupture of the longus capitis muscle is a rare and potentially life-threatening traumatic condition in horses, typically resulting from hyperextension of the head or a traumatic poll injury.

Seventeen horses of various breeds, aged between 3 months and 22 years, were presented primarily with bilateral epistaxis and retropharyngeal swelling at two referral equine hospitals between 2001 and 2024. One horse was presented with facial nerve paresis, whereas two horses were recumbent at the time of presentation.

Endoscopic examination revealed visible swelling of the medial wall and haemorrhage within the guttural pouches in all horses. All cases were diagnosed with rupture of the longus capitis muscle, basilar skull fractures were identified in four cases, and one horse also presented with an intrapouchal melanoma.

Medical treatment for all cases was primarily symptomatic and comprised a combination of nonsteroidal anti-inflammatory drugs, antibiotics, and fluid therapy. Anti-inflammatory and antibiotic treatment was maintained for a median of 8 days. Additionally, temporary tracheotomy was performed in five horses and median hospitalisation period was 11 days.

Thirteen horses were discharged, while four were euthanised during hospitalisation. Long-term follow-up ranging one to twelve years was available for ten horses. All discharged horses made a complete recovery.

Long-term follow-up provided for ten horses emphasizes the favorable prognosis for complete recovery after rupture of the LCM in horses.

Keywords: longus capitis, muscle, rupture, epistaxis, guttural pouch

MOLECULAR PREVALENCE OF EQUINE PIROPLASMOSIS IN ISTRIA REGION

Nika Konstantinović^{1*}, Franka Emilija Čulina², Nika Delić², Petra Bratić³, Ema Gagović⁴
Jelena Gotić³, Daria Jurković -Žilić⁴, Antun Kostelić⁵, Dora Višal², Relja Beck⁴

¹Department of Parasitology and Parasitic Disease with Clinic, Faculty of Veterinary Medicine, University of Zagreb, Zagreb, Croatia

²Student, Faculty of Veterinary Medicine, University of Zagreb, Zagreb, Croatia

³Clinic for Internal Diseases, Faculty of Veterinary Medicine, University of Zagreb, Zagreb, Croatia

⁴Laboratory for Parasitology, Croatian Veterinary Institute, Zagreb, Croatia

⁵Department of Animal Science, Faculty of Agriculture, University of Zagreb, Zagreb, Croatia

*corresponding author: Nika Konstantinović, nkonstantinovic@vef.hr

Equine piroplasmosis (EP) is one of the most prevalent vector-borne diseases in horses, caused by intracellular parasites *Babesia caballi*, *Theileria equi*, and *Theileria haneyi*. Due to its impact on equine health and its economic consequences, EP is included in the list of notifiable diseases by the World Organization for Animal Health. Croatia has a Mediterranean climate, mild winters, and an abundance of vectors. Nevertheless, there has been only one large-scale study on seroprevalence and molecular prevalence of EP, approximately ten years ago.

As part of the "Apicomplexan and bacterial tick-borne pathogens in domestic ruminants, horses and hematophagous vectors" project, 817 horse blood samples were collected across all regions of Croatia to assess the presence of equine piroplasmosis agents. Of these, 45 asymptomatic horses came from Medulin, Labin, and Hrboki in the Istria region. 23 mares and 22 geldings, aged 3 to 27 years were tested. Molecular analyses targeted the 18S rRNA gene of *Babesia/Theileria* spp.

Piroplasmid DNA was detected in 25 of 45 samples (55%). Three horses tested positive for *B. caballi*, while the rest were positive for *T. equi*. Both A and A1 genotypes of *T. equi* were found.

This study demonstrates a high prevalence of EP agents in the horse population in Istria. The high prevalence of ticks in the coastal regions of Croatia makes them EP hotspots. Due to climate change, vector-borne diseases are expected to spread outside known regions. Continuous animal surveillance and targeted control measures of vectors are imperative for the control of EP.

Keywords: equine piroplasmosis, vector borne diseases, *Babesia caballi*, *Theileria equi*

FIRST EVIDENCE OF *THEILERIA EQUI* INFECTION IN APPARENTLY HEALTHY DONKEYS FROM CROATIA

Nika Konstantinović¹, Ema Gagović², Jelena Gotić³, Daria Jurković-Žilić², Antun Kostelić⁴, Gordan Šubara⁵, Relja Beck²

¹Department of Parasitology and Parasitic Disease with Clinic, Faculty of Veterinary Medicine, University of Zagreb, Zagreb, Croatia

²Laboratory for Parasitology, Croatian Veterinary Institute, Zagreb, Croatia

³Clinic for Internal Diseases, Faculty of Veterinary Medicine, University of Zagreb, Zagreb, Croatia

⁴Department of Animal Science, Faculty of Agrobiotechnical Sciences Osijek, J.J. Strossmayer University, Osijek

⁵Agency for Rural Development of Istria, Pazin, Croatia

*corresponding author: Nika Konstantinović, nkonstantinovic@vef.hr

Equine piroplasmosis (EP) is one of the most widespread vector-borne diseases of equines worldwide. Horses, donkeys, zebras and mules can be infected, although horses appear to be the most susceptible. Most studies have focused on horses, primarily in endemic countries, while data on donkeys remain limited. To date, no large-scale studies on tick-borne piroplasm infections in the donkey population of Croatia have been conducted, and only a few such studies are available for donkeys in Europe overall.

In this study, a total of 134 blood samples were collected from apparently healthy donkeys across coastal and continental regions of Croatia, including Istria, the islands of Pelješac, Krk and Rab, and the regions of Šibenik-Knin, Lika-Senj and Zagreb. Molecular analyses targeted the 18S rRNA gene of *Babesia/Theileria* spp. DNA was extracted using the DNeasy® Blood and Tissue Kit on a QIAcube® automated system. PCR products were analyzed by capillary electrophoresis (QIAxcel), purified and sequenced (Macrogen Inc.). Assembled sequences were compared with reference sequences deposited in public databases.

Out of 134 samples, piroplasmid DNA was detected in 33 (24.62%) animals. Sequencing revealed only *Theileria* spp., clustering into two distinct sequence groups consistent with *Theileria equi* genotypes. All positive donkeys originated from coastal areas (Istria, Šibenik-Knin region and the island of Pelješac), while animals from continental regions tested negative.

This study demonstrates, for the first time, that apparently healthy donkeys in Croatia are infected with *T. equi*, with at least two distinct genotypes circulating in this host species. Given the limited data available for donkeys elsewhere and the variable prevalences reported from other regions, our findings provide an important contribution to understanding the occurrence and geographic distribution of *T. equi* in European donkey populations.

Keywords: equine piroplasmosis, *Theileria equi*, donkeys, Croatia

EQUINE SESSION
POSTER PRESENTATIONS

BILATERAL GONADAL TERATOMA IN A LIPIZZANER COLT

Luka Spelic^{1*}, Andrea Klang², Rabea Haddad¹

¹*Equine Surgery Unit, Department of Companion Animals and Horses, University Equine Hospital, University of Veterinary Medicine Vienna, Veterinärpl. 1, Vienna, Austria*

²*Unit of Pathology, Department of Biological Sciences and Pathobiology, University of Veterinary Medicine Vienna, Veterinärpl. 1, Vienna, Austria*

**corresponding author: Luka Spelic, luka.spelic@vetmeduni.ac.at*

Teratomas are rare, pluripotent germ cells tumors, predominantly occurring in colts and young stallions. Typically unilateral, benign and asymptomatic, these tumors most commonly occur in undescended testicles. Teratomas can manifest different abnormal histological findings, originating from all embryonic germ layers, such as skin, muscle, fat, tooth structure, hair, bone or cartilage. Diagnosis of teratomas is normally made during elective castrations of cryptorchid stallions.

This report describes a case of a 1.5-year-old Lipizzaner colt presented to University of Veterinary Medicine in Vienna, Austria, for elective castration. Clinical examination and pre-operative hematology and biochemistry results were within normal limits. However, palpation of both gonads reported their consistency as firmer than normal.

Castration was performed via a scrotal approach with an open technique. Upon removal of the testicles and epididymides, both epididymides appeared enlarged (circular and 3 cm of diameter) and heterogenous on palpation and with multiple black foci visible within parenchyma upon dissection. Samples were sent for histologic examination.

Histology reported complex formation composed of epithelial and mesenchymal tissue components, including collagenous connective tissue, adipose tissue, lymphatic tissue, nerve tissue, glandular epithelium, and keratinizing squamous epithelium, consistent with a diagnosis of Teratoma.

To the best of our knowledge, this is the first report of bilateral descended testicular teratoma in a clinical case of a colt. This case highlights the importance of thorough examination of both testes during routine castration, even in a fully descended testicles or without overt clinical abnormalities.

Keywords: teratoma, stallion, gonads, tumor, descended

INFECTIOUS ENDOCARDITIS IN A TWO-WEEK-OLD FOAL: CASE REPORT

Thibaud Olivier Marie Guichardiere^{1*}, Jelena Gotić², Nika Brkljača Bottegaro³, Katarina Miljak³, Marin Torti²

¹Faculty of Veterinary Medicine, University of Zagreb, Zagreb, Croatia, student

²Clinic for Internal Diseases, Faculty of Veterinary Medicine, University of Zagreb, Zagreb, Croatia

³Clinic for Surgery, Orthopaedics and Ophthalmology, Faculty of Veterinary Medicine, University of Zagreb, Zagreb, Croatia

**corresponding author: Thibaud Olivier Marie Guichardiere, thibaudguichardiere@yahoo.com*

Sepsis is the leading cause of mortality in foals during the first weeks of life, with failure of passive transfer of colostral antibodies recognized as a major predisposing factor. Affected foals typically present with tachycardia, tachypnea, depression, anorexia, colitis, and fever. In this report we describe a severe case of neonatal sepsis complicated by multiple comorbidities.

A two-week-old foal was admitted for an acute onset of bilateral hyphema. At admission, the foal was alert with normal vital signs, a 4/6 holosystolic murmur and mild effusion of the tibiotarsal joints. Blood results revealed marked leukocytosis, increased serum amyloid A (SAA), decreased iron, mild anemia, hypoproteinemia and negative blood culture.

Anterior uveitis and hypopyon were diagnosed on ophthalmic examination. Echocardiography revealed vegetative/erosive lesion consistent with infectious endocarditis. Thoracic radiographs and abdominal ultrasound were unremarkable. Synovial fluid analysis showed a low protein count and low cellularity, no evidence of marked inflammation or infectious agents; both aerobic and anaerobic bacterial cultures were negative. Because of the poor prognosis the owner elected humane euthanasia.

Infective endocarditis in foals carries a poor prognosis and early diagnosis is a critical determinant of successful management. Although septic foals can survive to discharge and pursue a racing career, multisystemic disease, and endocarditis are associated with worse short- term outcomes and reduced long-term performance. This report, as a rare case of infectious endocarditis in foals, emphasizes the importance of comprehensive assessment and realistic prognostic counselling in severe neonatal sepsis.

Keywords: foal, neonatal sepsis, infective endocarditis, hyphema, prognosis

ESOPHAGEAL OBSTRUCTION AS A POTENTIAL CLINICAL MANIFESTATION OF PITUITARY PARS INTERMEDIA DYSFUNCTION IN HORSES

Ana Ivanković¹, Matea Markušić¹, Petra Bratić², Darko Grden², Jelena Gotić^{2*}

¹ Faculty of Veterinary Medicine, University of Zagreb, Zagreb, Croatia

² Clinic for Internal Medicine, Faculty of Veterinary Medicine, University of Zagreb, Zagreb, Croatia

*corresponding author: Jelena Gotić, jselanec@vef.hr

Pituitary pars intermedia dysfunction (PPID) is a progressive endocrine disorder of older horses, caused by increased secretion of proopiomelanocortin peptides from an enlarged pars intermedia. Typical clinical signs include hirsutism, hyperhidrosis, muscle atrophy, polydipsia, polyuria, abnormal fat distribution, lethargy, insulin dysregulation, and laminitis. Esophageal obstruction (choke) is the most common esophageal disorder in horses and is characterized by regurgitation with excessive nasal discharge, dysphagia, ptyalism or coughing, extension of the head and neck after eating, and restlessness.

This report describes three horses with recurrent esophageal obstruction that were concurrently diagnosed with PPID. Two of the three horses (20-year-old gelding and 15-year-old mare) were referred for gastroscopy due to weight loss, and both had a history of repeated dysphagia and recurrent choke episodes. The third horse, a 17-year-old mare, presented with acute esophageal obstruction and also had a history of multiple episodes. Gastric squamous mucosal ulceration (grade 2/4) was identified in one horse, while the remaining two showed no gastroscopic abnormalities.

All three horses were tested for PPID using basal plasma ACTH concentrations, which were increased, confirming Equine PPID. Following initiation of pergolide therapy (1 mg/day), no further episodes of esophageal obstruction were observed in any of the horses, and improvements in coat quality, body condition score, and muscle condition were noted.

No descriptions of esophageal obstruction in horses with PPID were found in the literature, even in studies including large horse cohorts. Although esophageal obstruction is not typically recognized as a clinical sign of PPID and routine diagnostic workup does not usually include ACTH testing, these cases suggest a potential association. Including endocrine testing in the evaluation of geriatric horses with recurrent esophageal obstruction may improve diagnosis and clinical management.

Keywords: esophageal obstruction, choke, PPID, Cushing's disease, horse

COMMON VARIABLE IMMUNODEFICIENCY IN AN ADULT THOROUGHBRED GELDING: A COMPLEX MULTISYSTEMIC PRESENTATION

Zineb Kotbi¹, Slavko Žužul², Jurica Tršan^{3*}

¹Department of Veterinary Clinical Sciences, Purdue University, West Lafayette, USA

²Sandoz d.o.o., Zagreb, Croatia

³Department of Veterinary Clinical Sciences, Purdue University, West Lafayette, USA

*corresponding author: Jurica Tršan, jtrsan@purdue.edu

A 14-year-old Thoroughbred gelding was evaluated for fever, intermittent colic, and cough. Initial examination revealed lymphadenopathy, dehydration, and respiratory noise. Diagnostic imaging identified pulmonary B-lines, pleural effusion, hepatic nodularity, and a right renal mass. Tracheal wash cytology confirmed severe neutrophilic inflammation, and culture identified *Rhodococcus equi*, *Streptococcus equi* subsp. *equi*, and *Actinobacillus equuli*. Additional abnormalities included peritonitis, internal abscesses, EGUS grade 2, and right-sided uveitis.

Bloodwork consistently demonstrated leukocytosis, hypoalbuminemia, and anemia with limited improvement despite broad-spectrum antimicrobials and supportive therapy. Ongoing refractory inflammation and poor clinical response prompted evaluation for immunodeficiency. Flow-cytometric immunophenotyping demonstrated markedly reduced B-cell populations, while serum immunoglobulin quantification revealed decreased IgG and IgM. Antigen-specific titers confirmed inadequate humoral responses to *R. equi* and *S. equi*. These findings supported a diagnosis of common variable immunodeficiency (CVID).

CVID is a rare, acquired immunodeficiency of adult horses characterized by impaired B-cell function and failure to produce sufficient immunoglobulins, predisposing affected individuals to chronic or disseminated infections and poor therapeutic response. In this case, CVID provided the unifying explanation for the horse's progressive pneumonia, opportunistic infections, ocular inflammation, and inability to recover. Due to clinical deterioration and a grave prognosis, humane euthanasia was elected.

Keywords: equine, CVID, immunodeficiency, *Rhodococcus equi*, *Streptococcus equi*, pneumonia, B-cell dysfunction

THE DISTRIBUTION OF INDIGENOUS DONKEY BREEDS IN CROATIA

Niko Popović¹, Tomislav Mašek², Mladenka Vukšić³, Matija Jurić⁴, Maja Maurić Maljković^{1*}

¹Department of Animal Breeding and Livestock Production, Faculty of Veterinary Medicine, University of Zagreb, Zagreb, Croatia

²Department of Animal Nutrition and Dietetics, Faculty of Veterinary Medicine, University of Zagreb, Zagreb, Croatia

³Department of Hygiene, Technology and Food Safety, Faculty of Veterinary Medicine, University of Zagreb, Zagreb, Croatia

⁴Faculty of Veterinary Medicine, University of Zagreb, Zagreb, Croatia

**corresponding author: Maja Maurić Maljković, mmauric@vef.unizg.hr*

Donkeys in Croatia were historically found mainly in the Mediterranean regions – specifically in Istria, the Dinaric area, and the islands. They played an important role as transport and riding animals, and in the cultivation of small agricultural plots. In the mid-20th century, the donkey population in Croatia exceeded 50,000, but by the 2000s their numbers had declined significantly (according to some data, by more than 80%), placing them in the category of critically endangered breeds according to the FAO. In recent years, efforts have been made to develop new models for the economic use of donkeys. Their main role has shifted from working animals to animals used for milk and meat production (the latter only in Istria County), tourism, and leisure, resulting in a slow but steady increase in their numbers since the 2000s. Today, most of the donkey population remains in the Mediterranean regions – Šibenik-Knin (13.51%), Istria (12.74%), Zadar (11.90%), and Split-Dalmatia County (11.84%)—but, due to different models of utilisation, their numbers are also rising in some central Croatian counties – Bjelovar-Bilogora (8.93%), Karlovac (5.84%), and Sisak-Moslavina (4.84%). By breed, the highest numbers of Istrian and North Adriatic donkeys are found in Istria County (62.17% and 48.50%, respectively), while the Littoral Dinaric donkey is most common in Dalmatia, particularly in Šibenik-Knin (15.08%), Zadar (14.42%), and Split-Dalmatia County (14.25%). The shift in donkey utilisation, the slow but steady increase in their numbers, and their spread to other regions of Croatia provide modest indications of a potential path to population recovery and highlight the importance of maintaining ongoing conservation efforts for indigenous Croatian donkey breeds.

Keywords: donkey, population, indigenous breeds, biodiversity

STRAIGHT DISTAL SESAMOIDEAN LIGAMENT DESMITIS TREATED WITH EXTRACORPOREAL SHOCK WAVE THERAPY – A CASE REPORT

Ira Seferagić Pliško^{1*}, Zoran Vrbanac², Anita Kraljević², Ana Javor², Petra Bratić³, Jelena Gotić³, Katarina Miljak⁴, Nika Brkljača Bottegaro⁴

¹*Faculty of Veterinary Medicine, University of Zagreb, Zagreb, Croatia*

²*Department of Radiology, Ultrasound Diagnostics, and Physical Therapy, Faculty of Veterinary Medicine, University of Zagreb, Zagreb, Croatia*

³*Clinic for Internal Diseases, Faculty of Veterinary Medicine, University of Zagreb, Zagreb, Croatia*

⁴*Clinic for Surgery, Orthopaedics, and Ophthalmology, Faculty of Veterinary Medicine, Zagreb, University of Zagreb, Croatia*

**corresponding author: Ira Seferagić Pliško, iseferagicplisko@vef.hr*

Extracorporeal Shock Wave Therapy (ESWT) is increasingly used in equine orthopaedic pathologies. Straight sesamoidean ligament (SDSL) desmitis is a rare soft tissue injury that causes lameness of the distal limb. The prognosis for SDSL desmitis is guarded, with about 50% of horses returning to work and roughly 30% regaining their previous level of performance.

A 9-year-old Warmblood mare used for dressage was presented with intermittent right forelimb lameness lasting six weeks. Clinical examination revealed mild pain on palpation of palmar aspect of the proximal phalanx, flexion of the fetlock and lameness 3/5 on the right forelimb. The palmar digital nerve block was negative and the lameness was abolished with the abaxial sesamoid block. Radiography revealed no abnormalities. Ultrasonography identified a focal hypoechoic lesion with fiber disruption in the lateral SDSL (P1B–P1C).

Treatment involved controlled hand-walking and four focused ESWT sessions at two-week intervals (1500 shocks at 0.748 mJ/mm, 5 Hz). Upon re-examination after 7 weeks, lameness improved to 2/5. Ultrasonography revealed increased echogenicity and improved fiber alignment.

Straight sesamoidean ligament desmitis should be considered in cases of lameness of the distal limb, even in the absence of swelling. Ultrasonography represents a reliable diagnostic tool for identifying the lesion, potentially reducing the need for MRI evaluation. The use of ESWT with controlled exercise can support ligament healing and improve clinical outcome.

Keywords: horse, straight distal sesamoidean ligament, ESWT, desmitis

Acknowledgements: The authors thank and acknowledge Multi Radiance Medical for providing the MPACTVet device; the company had no role in study design, data collection, analysis, or interpretation.

**EXOTIC AND WILD ANIMALS
SESSION
ORAL PRESENTATIONS**

EVALUATION OF THE BUNNY WRAP METHOD RESTRAINT TECHNIQUE FOR CT IMAGING IN RABBITS: A ONE-YEAR EXPERIENCE

Ana Javor^{1*}, Gabrijela Jurkić Krsteska², Barbara Mratović¹, Petar Krolo³, Hrvoje Capak¹, Zoran Vrbanac¹

¹*Department of Radiology, Ultrasound Diagnostic and Physical Therapy, Faculty of Veterinary Medicine, University of Zagreb, Zagreb, Croatia*

²*Clinic for Internal Medicine, Faculty of Veterinary Medicine, University of Zagreb, Croatia*

³*PhD student, Faculty of Veterinary Medicine, University of Zagreb, Croatia*

**corresponding author: Ana Javor, ajavor@vef.unizg.hr*

Safe and effective immobilization is essential for obtaining high-quality diagnostic images in small mammals. Traditionally, general anaesthesia has been used to minimize motion artefacts during computed tomography (CT). However, pharmaceutical restraint carries significant risks in rabbits, including cardiopulmonary depression, delayed recovery, hypothermia and increased mortality as they are highly sensitive to anaesthesia.

To address these limitations, a non-pharmacological restraint method known as the “bunny wrap” was implemented in our facility and retrospectively evaluated over a one-year period. The technique involves gently securing the rabbit in a soft fleece wrap, allowing comfortable immobilization without distress, while maintaining normal respiration. A total of 25 CT procedures were performed and assessed in the Veterinary Teaching Hospital using this method, primarily for dental or ear canal pathologies, vestibular syndrome and soft-tissue evaluation. Diagnostic image quality was comparable to that obtained under light sedation, with a marked reduction in adverse physiological responses and post-procedural recovery time. Mild motion artefacts were observed, usually related to respiratory movement. No injuries, overheating or stress-related complications were recorded. All cases were imaged successfully. One case (4%) required repeat scans due to significant motion artefacts, which increased the absorbed dose of ionising radiation. This method has significant limitations in the assessment of the lungs and should be approached carefully because of potentially sub-adequate image quality.

The results of this study confirm “bunny wrap” technique as a safe, efficient and welfare-oriented alternative to pharmaceutical restraint for CT imaging in rabbits for certain indications, reducing anaesthetic risk while maintaining diagnostic reliability. Further studies are warranted to standardize the method and assess applicability to other small animal species.

Keywords: Bunny wrap, computed tomography, animal welfare

EURASIAN LYNX (*LYNX LYNX*) MORTALITY IN CROATIA IN THE 2013 – 2023 PERIOD

Matea Kulušić¹, Magda Sindičić^{2*}, Ira Topličanec², Vedran Slijepčević³, Josip Kusak⁴, Tomislav Gomerčić⁴

¹*Student, Faculty of Veterinary medicine University of Zagreb, Zagreb, Croatia*

²*Department of Hunting and wildlife, Faculty of Veterinary Medicine University of Zagreb, Zagreb, Croatia*

³*Karlovac University of Applied Sciences, Karlovac, Croatia*

⁴*Department of Veterinary Biology, Faculty of Veterinary Medicine University of Zagreb, Zagreb, Croatia*

**corresponding author: Magda Sindičić, msindicic@vef.unizg.hr*

The Eurasian lynx (*Lynx lynx*) is strictly protected species in Croatia, and its population is systematically monitored, including the collection of mortality data. Along with natality and migration, mortality represents a core demographic factor that influences population size and structure. Mortality patterns provide valuable insight into population dynamics and long-term viability. Understanding the frequency and causes of mortality is therefore essential for identifying threats and guiding effective conservation strategies.

This study analysed Eurasian lynx mortality in Croatia from 2013 to 2023. During the 11-year period, 24 lynx deaths were documented: 8 males and 6 females; 12 adults and 7 cubs, while sex and age could not be determined for the remaining individuals. In 8 cases death could not be confirmed with material evidence but was documented based on reliable source. The majority of cases (75 %) were directly or indirectly linked to anthropogenic factors, primarily illegal killing (37,5% suspected and 8,3% confirmed illegal killings) and traffic collisions (12,5%). Natural causes were less common, with orphaned cubs representing a particularly vulnerable category. For two individuals, the cause of death could not be determined. Spatial distribution analysis showed that most mortality events occurred in the Lika and Gorski kotar regions, coinciding with the core distribution area of the Croatian lynx population.

These findings are consistent with mortality patterns reported over the previous 40-year period in Croatian and in other European regions and contribute to ongoing conservation planning for this endangered species.

Keywords: Eurasian lynx, *Lynx lynx*, mortality, anthropogenic factors, population monitoring

SECONDARY NUTRITIONAL HYPERPARATHYROIDISM IN A CAPTIVE CHINESE STRIPED-NECK TURTLE (*MAUREMYS SINENSIS*)- A CASE REPORT

Helena Potet¹, Siniša Faraguna², Ana Javor³, Josip Miljković⁴, Dražen Đuričić^{5*}

¹student, Faculty of Veterinary Medicine, University of Zagreb, Zagreb, Croatia

²Department of Pathophysiology, Faculty of Veterinary Medicine, University of Zagreb, Zagreb, Croatia

³Department of Radiology, Ultrasound Diagnostics and Physical Therapy, Faculty of Veterinary Medicine, University of Zagreb, Zagreb, Croatia

⁴Department of Physiology and Radiobiology, Faculty of Veterinary Medicine, University of Zagreb, Zagreb, Croatia

⁵Department of Poultry Diseases with Clinic, Faculty of Veterinary Medicine, University of Zagreb, Zagreb, Croatia

*corresponding author: Dražen Đuričić, drazen.djuricic@vef.unizg.hr

A 12-year-old male Chinese striped-neck turtle (*Mauremys sinensis*) was presented to the Clinic for Birds and Exotic Animals at the Faculty of Veterinary Medicine in Zagreb, due to intermittent oral bleeding unresponsive to antibiotics. The animal had been kept in an aquarium without a terrestrial area, heating lamp, water heater, or filtration, with UVA/UVB lighting added only recently. Its diet consisted of Reptomin® pellets, lettuce, and cuttlebone without supplementation, suggesting chronic nutritional imbalance.

Clinical examination showed good body condition (BCS 6/9; 787.6 g) but dry, thickened forelimb skin, limb deformities, pale oral mucosa, and a soiled cloaca with reddish feces. Radiographs revealed skeletal deformities consistent with nutritional secondary hyperparathyroidism (NSHP). Fecal testing was negative for endoparasites. Biochemistry showed hypocalcemia relative to phosphorus (Ca 2.80 mmol/L, P 2.07 mmol/L), and marked hyperuricemia (1190 µmol/L), indicating renal dysfunction. Hematology revealed severe normocytic, normochromic anemia (RBC 0.2 ×10⁶/µL; Ht 14%; Hb 2.72 g/dL) and leukocytosis (65.8 ×10³/µL). Therapy included intramuscular vitamin AD₃E and iron, subcutaneous fluids (Ringer solution and Metabolase, 4:1), and assisted feeding with Emerald Omnivore, which induced regurgitation and acute oral and nasal bleeding. Despite treatment, the condition deteriorated, and euthanasia was performed. Necropsy showed hepatomegaly, renomegaly, and diffuse hemorrhages of all coelomic organs.

The case demonstrates the systemic consequences of chronic inadequate husbandry and diet, including NSHP, renal and hepatic dysfunction, coagulopathy, and hemorrhage. Proper UVB exposure, optimal temperature ranges, and balanced calcium-to-phosphorus intake are crucial for preventing metabolic and systemic disease in chelonians.

Keywords: chelonian, *Mauremys sinensis*, nutritional secondary hyperparathyroidism, hemorrhagic syndrome, reptile husbandry

FIRST INSIGHTS INTO THE MOLECULAR DIVERSITY OF DIPYLIDIUM AND JOYEUXIELLA IN CROATIA AND BOSNIA AND HERZEGOVINA

Ana Šikić^{1*}, Ema Gagović², Šimun Naletilić³, Daria Jurković Žilić², Adnan Hodžić⁴, Amer Alić⁵,
Magda Sindičić⁶, Relja Beck²

¹Department of Parasitology and Parasitic Disease with Clinic, Faculty of Veterinary Medicine, University of Zagreb, Zagreb, Croatia

²Laboratory for Parasitology, Croatian Veterinary Institute, Department of Microbiology and Parasitology, Zagreb, Croatia

³Laboratory for Pathology, Croatian Veterinary Institute, Department of Pathology, Zagreb, Croatia

⁴Centre for Microbiology and Environmental Systems Science (CMESS), Department of Microbiology and Ecosystem Science, Division of Microbial Ecology (DoME), University of Vienna, Vienna, Austria

⁵Department of Pathology, Faculty of Veterinary Medicine, University of Sarajevo, Sarajevo, Bosnia and Herzegovina

⁶Department of Hunting and wildlife, Faculty of Veterinary Medicine University of Zagreb, Zagreb, Croatia

*corresponding author: Ana Šikić, akajmic@vef.hr

Tapeworms (Cestoda, Platyhelminthes) from family Dipylidiidae are currently classified into three genera *Dipylidium*, *Diplopylidium* and *Joyeuxiella*, yet their taxonomy remains poorly resolved due to morphological uniformity and limited molecular data. Adult parasites inhabit the intestinal tract of carnivores, whereas larval forms parasitize various tissues, organs, or body cavities of both invertebrate and vertebrate hosts. Despite the broad distribution and zoonotic potential of Dipylidiidae tapeworms, research on their diversity and host associations in Croatia and Bosnia and Herzegovina remains sparse. To address this gap we sequenced mitochondrial gene fragments (*cox1* and *nad1*), to resolve species richness and assess genetic diversity in definitive hosts.

Adult tapeworms were collected from 240 examined definitive hosts (*Vulpes vulpes*, *Canis aureus*, *Felis catus*, *Ursus arctos*, *Meles meles*, *Martes* spp., *Canis lupus familiaris*, *Felis silvestris*, *Erinaceus europaeus*, *Canis lupus*). Five distinct sequences were detected within the genus *Joyeuxiella* and two within *Dipylidium*. *Joyeuxiella* spp. were confirmed in domestic cats, red foxes, golden jackals and stone martens. Both mitochondrial markers confirmed the presence of multiple genetically distinct *Joyeuxiella* lineages, including *J. pasqualei* sensu stricto, a divergent cluster consistent with *J. aff. pasqualei*, and highly divergent haplotypes potentially representing undescribed species. *Dipylidium caninum* was found in domestic cats, dog, European badger, and two major haplotypes of *D. caninum* were identified using both markers, corresponding to previously described feline and canine sequences.

Keywords: *cox1*, *nad1*, *Dipylidium caninum*, *Joyeuxiella pasqualei* sensu stricto, *Joyeuxiella* aff. *pasqualei*

OVARIAN CYST AND FOLLICLE DEVELOPMENT IN A FEMALE PEACH-FACED LOVEBIRD (*AGAPORNIS ROSEICOLLIS*) FOLLOWING SALPINGECTOMY

Matea Kapitanić¹, Maja Lukač², Emanuel Budicin², Dražen Đuričić²

¹student, Faculty of Veterinary Medicine, University of Zagreb, Zagreb, Croatia

²Department of Poultry Diseases with Clinic, Faculty of Veterinary Medicine, University of Zagreb, Zagreb, Croatia

³Department of Pathophysiology Faculty of Veterinary Medicine, University of Zagreb, Zagreb, Croatia

*corresponding author: Dražen Đuričić, drazen.djuricic@vef.unizg.hr

A 5-year-old female peach-faced lovebird (*Agapornis roseicollis*) was presented to the Avian Clinic, Faculty of Veterinary Medicine in Zagreb due to several days of straining. The owner reported attempted egg-laying the previous evening, with normal appetite and behavior. The bird had showed prolonged sexual activity and strong attachment to the owner. Two years earlier (August 8, 2024), it experienced egg retention with a large, horizontally positioned egg at the cloacal outlet followed by continuous laying of seven eggs and mild diarrhea likely related to reproductive activity. The bird lived mostly free in the household, receiving high owner contact; partial social isolation was implemented to reduce reproductive drive. The light cycle provided at least eight hours of darkness daily. Diet consisted of commercial seed mix, fruits, vegetables, and vitamins, but lacked calcium supplementation. Pericloacal oocentesis was performed, draining egg contents and retracting shell fragments into the oviduct, followed by salpingectomy several days later.

On October 17, 2025, clinical examination revealed BCS 4/5, weight 59 g, normal plumage, and appropriate responses. The crop was empty, and a soft, fluctuant 1-cm mass was palpable in the coelomic cavity. Radiographs were inconclusive; ultrasonography revealed several follicles of varying diameters and a larger ovarian cyst in the lower coelomic region. The bird was treated with enrofloxacin 15 mg/kg PO q12h for 10 days, supplemented with probiotics. Follow-up ultrasonography after nine days showed that follicles decreasing in size, and extended therapy for next 7 days. Preventive recommendations included dietary optimization with calcium and protein balance, environmental enrichment, and minimizing tactile stimulation to reduce recurrence. Long-term monitoring with regular ultrasonography was advised to detect early follicular development and prevent further reproductive complications.

Keywords: lovebird, *Agapornis roseicollis*, follicle cyst, follicle development, salpingectomy

CLINICAL APPLICATION OF PHOTOBIMODULATION THERAPY IN WILDLIFE REHABILITATION AT WILDRESCUE VEF RESCUE CENTRE

Kristina Popović¹, Tvrтко Mataušić¹, Dražen Đuričić², Maja Lukač^{2*}

¹Student, Faculty of Veterinary Medicine, University of Zagreb, Zagreb, Croatia

²Department of Poultry Diseases with Clinic, Faculty of Veterinary Medicine University of Zagreb, Zagreb, Croatia

**corresponding author: Maja Lukač, maja.lukac@vef.unizg.hr*

Photobiomodulation accelerates tissue repair, modulates inflammation, and enhances functional recovery in veterinary and human patients. High-irradiance Class IV lasers penetrate deep tissues, interacting with mitochondrial chromophores, primarily cytochrome c oxidase, enhancing ATP synthesis, stimulating fibroblast and keratinocyte proliferation, promoting collagen deposition, and supporting neovascularization. Using wavelengths of 635, 808, and 915 nm ($\pm 10\%$), the system enables multimodal stimulation while minimizing surface heating. Despite increasing clinical use, evidence on photobiomodulation in wildlife and exotic species remains limited.

From 2024 through 2025, a Class IV laser (doctorVet Plus, Italy) with a peak power of 16 W was employed to treat fourteen birds (raptors, scavengers, passerines), nine tortoises, and eight hedgehogs. Therapy followed predefined software-integrated protocols tailored to species, anatomical site, and lesion type. Indications included wing trauma, carapace injuries, and cutaneous wounds. Protocols addressed fractures, pain, inflammation, limb injuries, open wounds, infections, burns, and abscesses. Treatments lasted one to five weeks, with two to three weekly sessions adjusted by injury type and protocol.

Among birds, seven were released and seven died or were euthanized; of the tortoises, one was released, five remain under care, and three were euthanized; of the hedgehogs, three were released, two remain under care, and three died. No adverse effects associated with photobiomodulation were observed in any species.

Photobiomodulation appeared to enhance tissue healing, reduce captivity duration, and therefore minimize the negative impact of human contact, highlighting its potential as a promising tool in wildlife rehabilitation, while further clinical evaluation on larger cohorts is needed.

**EXOTIC AND WILD ANIMALS
SESSION
POSTER PRESENTATIONS**

TUMOR OCCURRENCE IN FREE-RANGING TERRESTRIAL MAMMALS FROM CROATIA: A RETROSPECTIVE HISTOPATHOLOGIC STUDY

Doroteja Huber^{1*}, Martina Hodinj², Ivana Mihoković Buhin¹, Branka Artuković¹, Dunja Vlahović¹, Lidija Medven Zagradišnik¹, Andrea Gudan Kurilj¹, Iva Ciprić¹, Ivan-Conrado Šoštarić-Zuckermann¹

¹Department of Veterinary Pathology, Faculty of Veterinary Medicine, University of Zagreb, Zagreb, Croatia

²Student, Faculty of Veterinary Medicine, University of Zagreb, Zagreb, Croatia

*corresponding author: doroteja.huber, dhuber@vef.hr

Free-ranging animals are increasingly becoming subjects of scientific research, driven by the growing emphasis on nature and biodiversity conservation. This study was conducted due to the limited research on tumors affecting free-ranging mammals both globally and in Croatia. The study analyzed histopathological slides from free-ranging terrestrial mammals diagnosed with a tumor, submitted either as tissue samples (which were collected from legally shot animals during hunting) or collected during necropsy. Following data were analyzed: species, sex, age, anatomical location of the tumor, tumor type, and biological behavior. Mortality (ratio between the number of deaths due to tumors and the total number of individuals in the studied population) and lethality rates (ratio between the number of deaths due to tumors and the total number of tumor-bearing individuals) were determined.

The study reviewed 349 archived samples dating from 2007 to 2024, identifying 9 tumors in 9 animals. Tumor occurrence was 2.6%. Mortality and lethality rates were 0%, as all animals died due to tumor-unrelated causes. Majority of tumors were benign (7 tumors, 77.8%). Diagnoses were cutaneous fibropapilloma (4 roe deer and 1 brown bear), cutaneous papilloma (1 mouflon), ovarian cystadenoma (1 brown bear), ovarian carcinoma (1 roe deer), and intestinal adenocarcinoma (1 brown bear). Age was unknown in all animals. Equal numbers of male and female animals were affected (4 animals each, 50% each; in 1 animal sex was unknown). Tumors were mostly diagnosed from tissue samples (8 animals, 88.9%). Affected locations were skin, ovary, and intestine.

This oncological study revealed a low tumor burden among free-ranging terrestrial mammals in Croatia. Affected animals were primarily diagnosed with benign tumors, with none of the tumors associated with death of the tumor-bearing animal. These findings contribute to our current knowledge of wildlife oncology, which is important in conservation of free-ranging populations, with potential applications in comparative oncology.

Keywords: wildlife oncology, tumor prevalence, histopathology, free-ranging terrestrial mammals, mortality, lethality

PRELIMINARY STUDY OF BLOOD FATTY ACID COMPOSITION OF FREE-RANGING GRAY WOLF FROM CROATIA

Antonio Bradić¹, Jasna Aladrović², Josip Kusak³, Lana Pađen^{2*}

¹Student of integrated under-graduate and graduate on Faculty of Veterinary Medicine University of Zagreb, Zagreb, Croatia

²Physiology and Radiobiology, Faculty of Veterinary Medicine University of Zagreb, Zagreb, Croatia

³Veterinary Biology, Faculty of Veterinary Medicine University of Zagreb, Zagreb, Croatia

*corresponding author: Lana Pađen, lpaden@vef.unizg.hr

Composition of fatty acids (FAs) of different tissues can provide insight into feeding patterns, physiological status, and health assessment, which is essential for wildlife conservation. In most animals trans FAs (tFAs) originate from the diet and ruminant's meat is major dietary source. Literature shows that in canids metabolic pathways involving saturated (SFA) and monounsaturated FAs (MUFA) differ between sexes. Serum FAs composition is considered a reflection of short term or recent dietary intake, while erythrocytes (RBC) are a better long-term marker.

The FAs composition of the gray wolf blood has not yet been investigated, so aim of this study was to determine blood FA composition in both female (N=5; F) and male (N=4, M) free-ranging gray wolf in Croatia. The animals were captured during autumn/winter period to investigate movement and activity patterns, while blood samples were taken as a part of the health monitoring program. Total lipids of serum and RBC were extracted, and composition of FAs was determined by gas chromatography.

Serum and RBC of F and M were dominated by SFA (48.77±8.22% vs. 50.16±4.37; 54.34±6.33% vs. 52.73±8.00%). Polyunsaturated (PUFA) were second in representation in serum (30.50±6.20% vs. 36.83±4.53%) followed by MUFA (20.74±9.41% vs. 13.02±5.83%). Second in representation in RBC were MUFA (31.57±4.21% vs. 30.45±6.07%) then PUFA (14.09±5.00% vs. 16.32±3.63%). Essential (linoleic), and conditionally essential (arachidonic, AA) were significantly higher in F serum compared to F RBC (11.68±3.26 vs. 6.66±3.22%; 13.94±4.47% vs. 2.22±2.44%). Females had significantly lower essential α -linolenic FA in RBC compared to M RBC (0.35±0.13% vs. 0.78±0.33%). We determined one tFA in both genders and samples, although without significant difference.

Presence of tFA, ie. C16:1t, agrees with feeding habits comprising ruminants. Results also suggest possible sex-related differences but given the small sample number, further research is needed.

Keywords: fatty acids, gray wolf, blood samples, feeding habits, health status

NUTRITIONAL SECONDARY HYPERPARATHYROIDISM AND SEVERE DYSTOCIA IN A VEILED CHAMELEON (*CHAMAELEO CALYPTRATUS*): A CASE REPORT

Emanuel Budicin^{1*}, Liča Lozica¹, Dražen Đuričić¹, Željko Gottstein¹

¹*Department of Poultry Diseases with Clinic, Faculty of Veterinary Medicine, University of Zagreb, Heinzelova ulica 55, Zagreb, Croatia*

**corresponding author: Emanuel Budicin, e-mail: ebudicin@vef.hr*

Nutritional secondary hyperparathyroidism (NSHP), also known as metabolic bone disease, is a clinical condition that is caused by improper diet, lack of proper artificial or natural UVB or by combination of both factors which leads to an imbalance of calcium, phosphorus and vitamin D3.

A two-year-old female veiled chameleon (*Chamaeleo calyptratus*) was presented for clinical examination due to an one-week history of lethargy and limping on the right foreleg. The history revealed that she had similar symptoms in the past, but they lasted for a day or two. She had improper diet and environmental conditions, with no supplementary calcium or UVB lamp available.

The clinical examination revealed severe crepitations on all legs, an extremely distended abdomen and signs of periodontal disease. The radiographs of the whole body revealed multiple fractures on all limbs and some ribs. Every limb joint was deformed and the bones were extremely thin. In the whole coelom a dozen eggs were spotted and other organs were hard to recognize. Due to the severity of the generalized skeletal damage and the poor prognosis, the owner elected euthanasia. The necropsy showed the presence of 134 eggs filling the whole coelom, signs of gastroenteritis and fragile bones with multiple fractures in the whole skeletal system. Thus, a diagnosis of nutritional secondary hyperparathyroidism and dystocia was made.

Nutritional secondary hyperparathyroidism is a common disease in pet reptiles. This case serves as a critical reminder of the absolute necessity of proper husbandry for captive reptiles. Early and consistent preventative care is vital, as advanced NSHP often presents with complications that have a poor prognosis.

Keywords: Nutritional secondary hyperparathyroidism, Dystocia, Chameleon, fractures, husbandry

ANESTHETIC MANAGEMENT OF AN EURASIAN GRIFFON VULTURE (*GYPSS FULVUS*) UNDERGOING DIGIT AMPUTATION – A CASE REPORT

Ema Sajdl^{1*}, Ana Gross², Maja Lukač³, Petar Kostešić¹, Petra Dmitrović¹

¹*Clinic for Surgery, Orthopedics and Ophthalmology, Faculty of Veterinary medicine, University of Zagreb, Zagreb, Croatia*

²*Rotational internship program at Faculty of Veterinary medicine, University of Zagreb, Zagreb, Croatia*

³*Department of Poultry Diseases with Clinic, Faculty of Veterinary medicine, University of Zagreb, Zagreb, Croatia*

**corresponding author: Ema Sajdl, esajdl@vef.hr*

An Eurasian Griffon Vulture (*Gyps fulvus*) was admitted for amputation of the third digit of the left leg due to ischemic necrosis following a power cable injury.

Premedication consisted of midazolam 1 mg/kg IM, and the vulture was transported to the Clinic for Surgery, Orthopedics and Ophthalmology in a dark cage with its head covered to reduce stress. Upon arrival, additional midazolam 1 mg/kg IM and butorphanol 1 mg/kg IM were administered due to insufficient sedation. After 20 minutes sedation was sufficient, and general anesthesia was induced with isoflurane via face mask in sternal recumbency. Endotracheal intubation was performed using a laryngoscope and a 6.0 mm non-cuffed endotracheal tube. The vulture was then positioned in right lateral recumbency. Anesthesia was maintained with isoflurane (1–2%) delivered in 100% oxygen using a non-rebreathing system. A 24G catheter was placed in the right saphenous vein, and Hartmann's solution was administered at 10 mL/kg/h IV. Intraoperative analgesia included a butorphanol continuous rate infusion 0.1–2 mg/kg/h IV. Body temperature was supported by active warming. Continuous monitoring included electrocardiogram, capnography, pulse oximetry, end-tidal CO₂ and non-invasive blood pressure. Total duration of anesthesia was 75 minutes and completed without complications. To facilitate smoother and faster recovery flumazenil 0.01 mg/kg IV was given and postoperative analgesia included meloxicam 2 mg/kg IM. After extubation, the vulture was transported to a wildlife rehabilitation center in dark, quiet conditions. After a month of rehabilitation, the vulture was successfully released back to its natural habitat.

This case provides a detailed anesthetic protocol for Eurasian Griffon Vulture, a species for which limited anesthetic data are available, and demonstrates that the described approach was safe and efficient in achieving stable anesthesia and recovery.

Keywords: Eurasian Griffon Vulture, anesthesia, amputation, trauma

CASE OF COCCIDIOSIS IN THE GROUP OF GUINEA PIGS

Valentina Marić¹, Božana Barišić², Iva Ciprić³, Iva Čustović¹, Helena Đukić¹, Josipa Grginčić¹, Gabrijela Jurkić Krsteska⁴, Dora Višal¹, Nika Konstantinović^{2*}

¹Faculty of Veterinary Medicine, University of Zagreb, Zagreb, Croatia, student

²Department of Parasitology and Parasitic Disease with Clinic, Faculty of Veterinary Medicine, University of Zagreb, Zagreb, Croatia

³Department of Veterinary Pathology, Faculty of Veterinary Medicine, University of Zagreb, Zagreb, Croatia

⁴Clinic for Internal Diseases, Faculty of Veterinary Medicine, University of Zagreb, Zagreb, Croatia

*corresponding author: Nika Konstantinović, nkonstantinovic@vef.hr

Due to their small size and low price, guinea pigs (*Cavia porcellus*) are becoming increasingly popular as pets, often chosen as companions for children. Nevertheless, they are hosts to a number of parasite species and are often considered diagnostic and treatment challenge. *Eimeria caviae* is the only *Eimeria* species found in guinea pigs. Oval oocysts measuring 13-26 x 12-23 µm are found in feces, and developmental stages are present in the intestinal epithelium.

A newly acquired, young guinea pig was presented for examination due to softer stool and decreased appetite. The older guinea pig in the household and the other young guinea pig had the same symptoms. After several days, one of the young guinea pigs died and was sent for necropsy. Fecal samples from all animals were collected and submitted for coprological analysis. The remaining guinea pigs were treated with a combination of sulfadiazine and trimethoprim (30 mg/kg) s/c q24h for 3 days and then p/o q12h for 5 days. Strict hygiene measures were implemented, and follow-up testing was conducted after treatment.

Coprological analysis was performed using the flotation method and immunofluorescence test (IF). Multiple scrapings were taken from different locations of the intestinal wall.

Coprological analysis and examination of intestinal scrapings revealed the presence of thousands of *Eimeria caviae* oocysts, while IF was negative. Post-mortem findings confirmed coccidiosis as the definitive cause of death.

Despite the popularity of guinea pigs as pets and their close contact with children, a very small number of samples is submitted for coprological testing, even when clinical signs indicate possible parasitosis.

The goal of this case report is to draw attention to the guinea pigs as potential hosts for various parasites, some of which with zoonotic potential. Owners and veterinarians should be aware of the necessity for quarantine and parasitological fecal testing of newly acquired animals.

Keywords: Guinea pig, *Eimeria caviae*, endoparasites, protista

ENDOPARASITE PROFILES IN EUROPEAN HEDGEHOGS (ERINACEUS EUROPAEUS) ADMITTED TO A WILDRSCUEVEF REHABILITATION CENTRE

Višnja Bašić¹, Franjo Martinković², Maja Lukač³

¹Student, Faculty of Veterinary Medicine, University of Zagreb, Zagreb, Croatia

²Department of Parasitology and Invasive Diseases with Clinic, Faculty of Veterinary Medicine, University of Zagreb, Zagreb, Croatia

³Department of Poultry Diseases with Clinic, Faculty of Veterinary Medicine, University of Zagreb, Zagreb, Croatia

*corresponding author: Višnja Bašić, vbasic@vef.unizg.hr

European hedgehogs (*Erinaceus europaeus*) are one of the most frequently admitted mammal species to wildlife rescue centres across Europe and they are often infected with diverse ecto- and endoparasites.

This study examined the prevalence and species diversity of endoparasites in 49 hedgehogs (30 adults and 19 juveniles) admitted to the Wildlife Rescue Centre of the Faculty of Veterinary Medicine, University of Zagreb. Fresh faecal samples were collected from each and analysed using flotation with sugar and morphological identification.

Endoparasites were found in 33.33% of adults and 21.05% of juveniles. Most infections involved *Eucoleus* sp. eggs (64.29%) or *Crenosoma* sp. larvae (92.86%), with a single case of *Isospora* sp. oocysts. Among infected animals, 57.14% carried both *Eucoleus* sp. and *Crenosoma* sp. All infected adults were admitted in early spring or late autumn, while juveniles were all from one litter of four rescued in September. Overall prevalence of 28.57% was slightly lower than in comparable European studies. Clinical signs were observed in one adult animal that died suddenly and was found heavily infected with *Crenosoma* sp. lungworms at necropsy. The suggested seasonality may be linked to increased paratenic host activity and favourable environmental conditions in those seasons. Since all infected juveniles belonged to a single litter, conclusions should be interpreted with caution, as it may reflect a litter-specific exposure rather than the general juvenile population. This further supports the interpretation that the lower prevalence in juveniles likely reflects their shorter exposure to infective stages rather than a true absence of parasitic pressure.

Early detection of endoparasites enables timely treatment, reduces the risk of disease outbreaks and zoonotic risk and improves the welfare and survival prospects of admitted hedgehogs. Systematic monitoring is essential for effective patient care and broader wildlife health management.

Keywords: european hedgehog, endoparasites, *Eucoleus* sp., *Crenosoma* sp.

INITIAL CLINICAL ASSESSMENT AND APPROPRIATE HOUSING PROTOCOLS FOR BATS IN REHABILITATION FACILITIES

Tvrtko Mataušić¹, Kristina Popović¹, Maja Lukač^{2*}

¹Student, Faculty of Veterinary Medicine University of Zagreb, Zagreb, Croatia

²Department of Poultry Diseases with Clinic, Faculty of Veterinary Medicine University of Zagreb, Zagreb, Croatia

**corresponding author: Maja Lukač, mlukac@vef.hr*

Although rarely encountered in the wild, bats are a common group of patients in wildlife rehabilitation centres, often admitted due to human-wildlife interactions, domestic cat predation, or juvenile displacement from maternity roosts. As the only mammals capable of true powered flight, bats possess specialized anatomical and physiological adaptations, including specific dietary requirements, sensitivity to microclimate, and reliance on intact wing membranes, that necessitate species-specific examination, handling, and tailored rehabilitation protocols, making them among the most challenging taxa to manage in rehabilitation practice. Upon admission, bats should be screened for signs of lyssavirus infection, followed by a standardized physical examination using appropriate protective equipment, assessing mentation, hydration status, respiration, and musculoskeletal integrity, with attention to wings and digits. Newly admitted individuals are best housed in quarantine to monitor infectious and parasitic diseases. Housing design is critical, as bats are highly sensitive to light, humidity and temperature; enclosure materials and dimensions must therefore be selected according to species, age, and anticipated duration of care. Small carriers are suitable for short-term stabilization, whereas larger enclosures or terrariums are needed for extended care. Flight ability should be tested in a secure indoor environment to confirm adequate flight performance and endurance before release. Dehydration and wing injuries are the most common clinical findings and often determine rehabilitation duration. Recovery is strongly influenced by enclosure design, and flight testing reliably identifies individuals suitable for release. Future research should define species-specific enclosure design and microclimate needs, and standardize flight assessment to improve recovery, release decisions, and survival in rehabilitated bats.

Keywords: bat rehabilitation, wildlife rehabilitation, wing injury, enclosure design, flight assessment

WELFARE-BASED OBSERVATIONS ON CAPTIVE BREEDING OF WESTERN CAPERCAILLIE (*TETRAO UROGALLUS*) IN TWO AVIARY TYPES

Ivana Sabolek¹, I. Križ², Miljenko Bujanić¹, K. Krapinec³, Gordana Gregurić Gračner¹, Dean Konjević¹

¹ University of Zagreb, Faculty of Veterinary Medicine, Zagreb, Croatia

² Animal Protection Association "Tetrijeb", Goranska 158, Prezid, Croatia

³ University of Zagreb, Faculty of Forestry and Wood Technology, Svetošimunska 23, Zagreb, Croatia

*corresponding author: isabolek@vef.unizg.hr

The Western Capercaillie (*Tetrao urogallus*) faces population decline and habitat fragmentation across the central and southern parts of Europe, prompting the implementation of conservation measures. Aside from those oriented at habitat modelling, captive breeding stands as one of the potential conservation tools. However, low post-release survival reported in studies from other countries highlights the need for further research on breeding methods. The present study evaluates the behaviour of capercaillie housed in two aviary designs (n=8 animals, 2♂ and 6♀). The study was performed at the Middle-European Breeding Centre for capercaillie in Prezid, Croatia, in 2023-2024. The Type A aviary consists of three wooden compartments. The central one is for females (4 x 4 m; 3 m high), while each of the two side compartments houses a single male (3 m x 4 m; 3 m). The aviary is equipped with environmental enrichment features. The 16-cm openings between compartments allowed only females to move between compartments during the breeding season. The Type B aviary (72 x 72 m; 4–10 m) is located on a native lek site at 1006 m a.s.l., containing diverse vegetation mimicking the natural environment, an automatic feeder, and a shelter. In this aviary, both sexes are housed together. At first, animals were located in the Type A aviary, and then translocated to the Type B aviary. In Type A, female–female aggression was seen as well as laying eggs outside of provided nests, even on the sitting branch. A non-dominant male was observed to twitch tail feathers. In contrast, the Type B aviary supported more typical social and reproductive patterns, although occasional stress was present in juvenile males due to the presence of adult ones. These findings demonstrate that aviary design has a substantial influence on the behavioural indicators of welfare of captive capercaillie, playing an important role in captive-breeding management and potentially in the success of future reintroduction efforts.

Keywords: Capercaillie, behaviour, welfare, captivity

FARM ANIMALS SESSION
ORAL PRESENTATIONS

DETECTION AND GENOMIC PROPERTIES OF UNUSUAL ROTAVIRUS A STRAINS OF ZOONOTIC PORCINE ORIGIN IN HUMANS

Valentina Kunić^{1*}, Vjekoslava Kostanić¹, Sara Špoljar¹, Marina Prišlin Šimac¹, Ksenija Kretonić², Dubravka Vuković², Tea Čuti³, Draženka Vadla³, Dragan Brnić¹

¹Croatian Veterinary Institute, Department of Virology, Zagreb, Croatia

²Teaching Institute of Public Health of Osijek-Baranja County, Osijek, Croatia

³Institute of Public Health of Koprivnica-Križevci County, Koprivnica, Croatia

**corresponding author: Valentina Kunić, kunic@veinst.hr*

Rotavirus A (RVA) is a viral gastroenteritis-causing agent that infects various mammalian and avian species. While certain RVA strains are highly adapted to specific hosts, interspecies transmission, including sporadic zoonotic spillover, has been observed, raising public health concerns. The present study detected two cases of infection with zoonotic porcine-originated RVA strains in a human host, repeatedly revealing porcine to human RVA interspecies transmission occurring in Croatia. During 2024, fecal samples were collected from 73 human patients at the onset of gastrointestinal symptoms. Sampling was conducted in Osijek-Baranja and Koprivnica-Križevci Counties. RVA detection and quantification were performed using VP2 RT-qPCR. For genotyping, a subset of samples was tested with conventional RT-PCR targeting the VP7 and VP4 segments, followed by Sanger sequencing. Consequent to detecting two potentially zoonotic RVA strains, whole genome sequencing was conducted on two fecal samples. Complete RVA genomes were assembled via CLC Genomics Workbench combining reference based mapping and de novo assembly approach. Phylogenetic analysis was conducted for each RVA gene segment in MEGA 11 software.

The acquired zoonotic RVA genomes included G3P[6] and G4P[6] strains with typical porcine backbone constellations, displaying certain genetic heterogeneity. The zoonotic origin of human-derived porcine-like RVA strains was confirmed, as they clustered with domestic pig-derived, wild boar-derived, and porcine-like human zoonotic RVA strains previously detected in the Croatian ecosystem. The overlap of habitats between humans, and domestic pigs in rural and semi-urban areas poses a potential risk for infectious disease transmission, underscoring the importance of continuous surveillance of animal RVAs through the lens of the One-Health approach.

Keywords: Rotavirus A, human, domestic pig, interspecies transmission, zoonotic spillover, porcine origin, whole genome sequencing

BRAČ SHEEP AND ITS MATERNAL ORIGINS: PRELIMINARY MITOCHONDRIAL DNA FINDINGS

Jasna Kusanović¹, Ivan Vlahek², Velimir Sušić³, Maja Maurić Maljković²

¹PhD student, University of Zagreb, Faculty of Veterinary Medicine, Zagreb, Croatia

²Department of Animal Breeding and Livestock Production, University of Zagreb, Faculty of Veterinary Medicine, Zagreb, Croatia

³Professor emeritus, University of Zagreb, Faculty of Veterinary Medicine, Zagreb, Croatia

**corresponding author: Jasna Kusanović, kusanovicjasna@gmail.com*

Brač sheep is a distinct insular type of the Dalmatian Pramenka breed that has evolved under the unique environmental, cultural and pastoral conditions of the island of Brač. Shaped by centuries of extensive grazing on rocky pastures and limited seasonal resources, Brač sheep are characterised by their small body frame, hardiness, strong walking ability and suitability for producing high-quality lamb and dairy products.

Their long-term adaptation is reflected in specific biological and genetic characteristics. In addition, their close integration into traditional and local husbandry practices highlights their cultural and economic importance for island communities. The aim of this preliminary study was to assess the distinctiveness of the Brač sheep and to investigate its maternal origins using mitochondrial DNA markers.

To explore maternal origins, a 1035 bp fragment of mitochondrial DNA, including the control region, tRNA-Phe, and 12S rRNA coding region, was amplified from 20 adult ewes aging from 2 to 6 years from nine different flocks. Haplotypes were identified, assigned to haplogroups based on comparison with 397 reference sequences from NCBI, and visualised in a phylogenetic tree using the Neighbour-Joining method. The analysis also included assessment of variable nucleotide sites and haplotype diversity.

Fourteen distinct haplotypes were identified, all assigned to haplogroup B, the predominant maternal lineage in European sheep. The presence of multiple haplotypes within this geographically isolated population indicates preserved maternal diversity and aligns Brač sheep with other Mediterranean pramenka-type breeds.

Overall, the results provide the first genetic insight into the maternal structure of Brač sheep and document their current genetic status. These findings provide a baseline for future studies that incorporate larger sample sizes and additional molecular markers, with the aim of clarifying lineage structure and supporting the long-term conservation and formal recognition of this culturally and economically important island sheep population.

Keywords: sheep, pramenka, maternal lineage, mitochondrial DNA

MELATONIN TREATMENT ENHANCES POST-THAW SPERM FUNCTION IN FRENCH ALPINE BUCKS DURING THE NON-BREEDING SEASON

Ivona Žura Žaja^{1*}, Ivan Butković², Velimir Berta³, Hrvoje Valpotić⁴, Marko Samardžija², Martina Lojkić², Dražen Đuričić⁵, Suzana Milinković Tur¹, Vanja Lončarić⁶, Stefani Fruk Šimunec¹, Anamaria Ružić⁶, Silvijo Vince²

¹Department for Physiology and Radiobiology, Faculty of Veterinary Medicine, University of Zagreb, Croatia

²Clinic for Obstetrics and Reproduction, Faculty of Veterinary Medicine University of Zagreb, Croatia

³Veterinary station of Varaždin, Croatia

⁴Department for Animal Nutrition and Dietetics, Faculty of Veterinary Medicine, University of Zagreb, Croatia

⁵Department of Poultry Diseases with Clinic, Faculty of Veterinary Medicine, University of Zagreb, Croatia

⁶PhD Candidate, Faculty of Veterinary Medicine of University of Zagreb, Croatia

*corresponding author: Ivona Žura Žaja, izzaja@vef.unizg.hr

Reproductive activity in bucks shows a marked seasonal pattern, resulting in reduced semen quality during the non-breeding period. Melatonin, a hormone regulating photoperiodic reproduction, can be used to restore testicular activity and improve sperm function outside the breeding season. The aim of this study was to investigate the effects of exogenous melatonin on sperm vitality parameters of frozen-thawed ejaculates in French Alpine bucks during the non-breeding season.

Twelve sexually mature bucks aged 1.5–4 years were divided into two groups: melatonin-treated (MG, n=6) and control (CG, n=6). The experimental period lasted from March to May. Bucks in the MG group received four melatonin implants (74 mg) at the end of March. Semen was collected weekly by artificial vagina, centrifuged to separate seminal plasma, and sperm diluted with AndroMed® extender. After 24 h of cooling at +4°C, semen samples were gradually frozen and stored in liquid nitrogen (–196°C) until analysis. Thawing was performed by immersing the straws in a 38°C water bath for 30 s. Sperm vitality parameters, including plasma membrane and acrosome integrity, membrane permeability, chromatin stability, and mitochondrial activity, were assessed by flow cytometry. The melatonin-treated group showed significantly higher ($p < 0.05$) percentages of total live sperm ($42.5 \pm 1.8\%$ vs. $35.6 \pm 1.7\%$) and live sperm with intact acrosomes ($41.3 \pm 1.8\%$ vs. $34.3 \pm 1.7\%$), and a lower proportion of sperm with damaged plasma membranes ($57.6 \pm 2.3\%$ vs. $65.0 \pm 2.2\%$) compared to controls.

The results indicate that melatonin treatment during the non-breeding season enhances post-thaw sperm vitality and membrane integrity, supporting its potential use to improve semen quality and fertility in bucks under seasonal reproductive decline.

Keywords: buck, melatonin, frozen-thawed semen, sperm vitality, flow cytometry, non-breeding season, French Alpine breed

This research is a part of the preliminary research for GeSt Beef project supported by the Croatian Science Foundation under the project number [HRZZ- UIP-2025-02-8811].

TRAUMATIC RETICULOPERITONITIS IN A THREE-YEAR-OLD HOLSTEIN COW: A CASE REPORT

Petra Bratić^{1*}, Ivan – Conrado Šoštarić – Zuckermann², Jelena Gotić¹, Katarina Miljak³, Goran Štibrić⁴, Ivana Cvitaš⁴, Darko Grden¹

¹*Clinic for Internal medicine, Faculty of Veterinary Medicine, University of Zagreb, Zagreb, Croatia*

²*Department of Veterinary Pathology, Faculty of Veterinary Medicine, University of Zagreb, Zagreb, Croatia*

³*Clinic for Surgery, Orthopedics and Ophthalmology, Faculty of Veterinary Medicine, University of Zagreb, University of Zagreb, Zagreb, Croatia*

⁴*Zdenačka farma d.o.o., Croatia*

**corresponding author: Petra Bratić, pbratic@vef.unizg.hr*

A three-year-old holstein cow from a commercial dairy farm was admitted to the clinic with a ten-day history of progressive illness. Clinical examination revealed marked dehydration, continuous groaning, a positive Withers test and hypotonic rumen. Based on clinical findings and abdominal ultrasonographic evaluation, a presumptive diagnosis of a reticular foreign body was established. Due to poor general condition and unfavorable prognosis, the cow was euthanized. Postmortem examination confirmed the presence of a metallic wire-like foreign body (8.5 cm) penetrating the reticulum wall and forming a fistulous tract extending through the abdominal cavity. The tract involved the spleen, liver, and diaphragm, culminating in a purulent abscess (11 × 9 × 4 cm) on the thoracic side of the diaphragm. Multifocal fibrinopurulent adhesions were present between the omentum and parietal peritoneum.

This case highlights the diagnostic value of ultrasonography in thoracoabdominal disorders of ruminants and emphasizes the importance of early recognition of clinical signs suggestive of traumatic reticuloperitonitis (hardware disease).

Keywords: traumatic reticuloperitonitis, hardware disease, abdominal ultrasonography, Withers test

FARM ANIMALS SESSION
POSTER PRESENTATIONS

IMPACT OF SEX ON HOUSEKEEPING GENE STABILITY: LESSONS FROM GAPDH EXPRESSION IN THE PORCINE SMALL INTESTINE

Mirela Pavić Vulinović^{1*}, Mirna Mandić¹, Marija Ljubojević²

¹Department of Anatomy, Histology and Embryology, Faculty of Veterinary Medicine, University of Zagreb, Zagreb, Croatia

²Molecular Toxicology Unit, Institute for Medical Research and Occupational Health, Zagreb, Croatia

**corresponding author: Mirela Pavić Vulinović, mpavic@vef.unizg.hr*

Housekeeping genes, including glyceraldehyde-3-phosphate dehydrogenase (GAPDH), β -actin, and the 18S ribosomal RNA subunit, are commonly used as internal controls in PCR-based analyses due to their roles in essential cellular functions and the assumption of stable expression across physiological conditions. Emerging data suggest that the expression of housekeeping genes can vary depending on tissue type and sex, thereby affecting the reliability of quantitative analyses if sex is not incorporated as a variable.

To investigate this, we analyzed sex-associated differences in GAPDH expression in the small intestinal mucosa of domestic pigs (n = 5 per group). Total RNA was extracted from duodenal, jejunal, and ileal samples, reverse-transcribed, and quantified by RT-PCR. GAPDH expression was compared between sexes.

Results revealed significant sex-dependent variation in GAPDH expression across intestinal segments. Expression was higher in males in the duodenum, whereas females showed elevated levels in the jejunum. No statistically significant sex-related differences were observed in the ileum. These findings indicate that GAPDH does not maintain uniform stability along the small intestine and therefore cannot be considered a universally reliable housekeeping gene in porcine intestinal studies.

As housekeeping genes form the basis for normalization, any sex-related variability in their expression can skew relative quantification and compromise the validity of interpretations. These results underscore the importance of incorporating sex as a biological variable in molecular analyses and support the selection of housekeeping genes based on systematic stability assessment rather than convention.

Keywords: housekeeping genes, GAPDH, sex differences, pig intestine, RT-PCR

EFFECTS OF 2.4 GHZ RADIOFREQUENCY ELECTROMAGNETIC RADIATION ON DIFFERENTIAL LEUKOCYTE COUNTS IN BROILER PARENT FLOCK

Marinko Vilić^{1*}, Selim Pašić², Ana Shek Vugrovečki¹, Ivona Žura Žaja¹, Krešimir Malarić³, Nada Dolencić⁴, Metka Vlahek⁴, Željko Gottstein⁵ and Jadranka Pejaković Hlede¹

¹*Department of Physiology and Radiobiology, University of Zagreb, Faculty of Veterinary Medicine, Zagreb, Croatia*

²*Department of Physics, University of Zagreb, Faculty of Veterinary Medicine, Zagreb, Croatia*

³*Department of Communication and Space Technologies, University of Zagreb, Faculty of Electrical Engineering and Computing, Zagreb, Croatia*

⁴*Galivet d.o.o., Prelog, Croatia*

⁵*Department of Poultry Diseases with Clinic, University of Zagreb, Faculty of Veterinary Medicine, Zagreb, Croatia*

**corresponding author: Marinko Vilić, mvilic@vef.unizg.hr*

Previous studies have reported that exposure to radiofrequency electromagnetic field (RF-EMF) at the operating frequency used in wireless communication can cause serious functional disturbances in various animal species. For example, in birds (sparrow, stork, pigeon, chicken embryo), RF-EMF has been associated with increased embryo mortality and disorders of reproduction and circulation. However, knowledge of the effects of RF-EMF on avian haematological parameters is limited. The aim of this study was to investigate differential leukocyte counts in a parent breeder flock after exposure to RF-EMF. The parent breeder flock was divided into control (n = 50) and experimental (n = 50) group. The experimental group was exposed to RF-EMF at 2.4 GHz from two Wi-Fi routers for 19 consecutive days. The Wi-Fi routers were placed 1 m above the hens and 3 m apart. The average electric field to which the hens were exposed was approximately 100 mV/m. The radiofrequency electric field strength and frequency were measured at three locations using a portable spectrum analyzer NARDA SRM 3000 (NARDA, USA). Blood samples from females only (n = 10 per group) were collected before exposure (day 0) and on days 2, 5, 8, 14, and 19 of the experiment. Leukocyte differentiation was performed by the standard manual leukocyte differential method using microscopy (Olympus Europa Holding GmbH, Hamburg, Germany). Statistical analysis showed that the experimental group had significantly higher lymphocyte counts on days 5 and 19 ($P < 0.05$) and higher eosinophil counts on day 3 ($P < 0.05$), while monocyte counts were significantly lower on day 19 ($P < 0.05$) of the experiment. In conclusion, exposure of parent breeder flock to RF-EMF at a frequency of 2.4 GHz for 19 days causes alterations in differential leukocyte counts, with lymphocytes and eosinophils appearing to be the most sensitive parameters. Further research is needed to elucidate the mechanisms of differential blood cell count changes induced by RF-EMF.

Keywords: radiofrequency radiation, Wi-Fi, leukocytes, differential blood cell count, broiler breeder

ENVIRONMENTAL DISTRIBUTION AND BIOLOGICAL EFFECTS OF LEAD, COPPER, AND ZINC IN HONEYBEES (*APIS MELLIFERA*) ACROSS CONTRASTING LANDSCAPES

Snježana Kos^{1*}, Ana-Marija Kovač², Višnja Oreščanin³, Ivana Tlak Gajger⁴

¹*Spadent d.o.o., Zagreb, Croatia*

² *Department for Animal Nutrition and Dietetics, Faculty of Veterinary Medicine University of Zagreb, Croatia*

³ *Oreščanin Ltd., Zagreb, Croatia*

⁴ *Department for Biology and Pathology of Fish and Bees, Faculty of Veterinary Medicine University of Zagreb, Croatia*

**corresponding author: Ana-Marija Kovač, amkovac@vef.unizg.hr*

Honeybees are increasingly recognized as effective bioindicators for assessing environmental pollution across diverse landscapes. This study investigated concentrations of lead (Pb), copper (Cu), and zinc (Zn) in adult honeybees and honeybee pupae collected from three distinct locations: a meadow outside inhabited areas, a rural site by a highway, and an area adjacent to industrial facilities. A total of 24 samples, including both honeybee larvae and adult bees, were analyzed from each location. To measure the concentrations of metals in all honeybee samples, the source-excited energy dispersive X-ray fluorescence (EDXRF) method was employed, enabling multi-elemental, non-destructive analysis with high sensitivity.

Levels of all three elements varied by honeybee developmental stage and sampling site. The mean concentrations (mg/kg) for adult honeybees were: Pb 0.79 - 0.88, Cu 8.23 - 16.39, and Zn 65.89 - 87.52, and for honeybee pupae: Pb 0.58 - 0.70, Cu 7.46 - 14.58, and Zn 63.10 - 73.27, depending on sampling location. Concentrations of Pb and Cu were significantly affected by honeybee life stage, while Zn levels were influenced by both developmental stage and environment (all, $p < 0.05$). Regression analysis confirmed strong correlations for Pb and Cu with honeybee developmental stage, and for Zn with both life phase and location ($R = 0.68 - 0.85$; all $p < 0.05$).

These results demonstrate that both honeybee life stage and local environmental factors strongly influence the bioaccumulation of Pb, Cu, and Zn, emphasising the importance of careful environmental monitoring and risk assessment using managed honeybees as bioindicators.

DIET-RELATED ENERGETICS OF HONEYBEE LARVAE (*APIS MELLIFERA* L.)

Ana-Marija Kovač^{1*}, Maja Ivana Smodiš Škerl², Ivana Tlak Gajger³

¹Department for Animal Nutrition and Dietetics, Faculty of Veterinary Medicine University of Zagreb, Zagreb, Croatia

²Department for Livestock, Agricultural Institute of Slovenia, Hacquetova ulica 17, Ljubljana, Slovenia

³Department for Biology and Pathology of Fish and Bees, Faculty of Veterinary Medicine University of Zagreb, Zagreb, Croatia

*corresponding author: Ana-Marija Kovač, amkovac@vef.unizg.hr

Due to their specific ontogenic development, honeybees are classified as holometabolous insects. To build the adult body during metamorphosis, larvae accumulate biomass and store food reserves. There are limited data on the energy density of larvae in relation to different autumn feeding regimes of honeybee colonies.

This study aims to investigate the efficiency of supplementary feeding with protein, pollen, and spirulina-enriched sugar candy on the development of honeybee larvae using calorimetric analysis.

In the apiary, after the last honey extraction in August 2024, thirty-six honeybee colonies were divided into four feeding groups (nine colonies per group): (I) sugar syrup (1:1), (II) commercial protein candy, (III) pollen candy, and (IV) 2% spirulina-enriched sugar candy. Larvae were sampled directly from wax combs on days 0, 22, and 43. Lyophilized samples underwent bomb calorimetry (IKA C6000 global standard, Staufen, Germany) to determine gross energy (GE) content in MJ/kg. Compared to the control sampling (day 0), during the second sampling (day 22), groups I, II, and IV had lower energy levels, while the group fed protein candy (II) showed higher GE. In the samples collected during the third sampling period (day 43), groups I, III, and IV had significantly higher GE compared to the control sampling, with groups I (22.31 ± 0.56 MJ/kg) and IV (22.20 ± 0.8 MJ/kg) showing the highest energy density (all, $p < 0.05$).

The results highlight significant differences between feeding groups and sampling periods, demonstrating a substantial impact of supplementary feeding on energy content during honeybee ontogenesis, with sugar syrup, pollen, and spirulina-enriched sugar candy showing the most significant results. Integrating calorimetric investigations could significantly affect honeybee colony development, particularly by evaluating the energy effects of supplementary feeding.

Keywords: *Apis mellifera*, honeybee larvae, supplementary feeding, calorimetry

**VETERINARY PUBLIC HEALTH
SESSION
ORAL PRESENTATIONS**

EFFECTS OF THE FREEZING PROCESS ON THE PHYSICAL AND CHEMICAL PROPERTIES OF BEEF FROM DIFFERENT BREEDS AND SEXES

Katarina Smolčić¹, Mladenka Vukšić^{2*}, Željka Cvrtila², Tomislav Mikuš²

¹DVM

²University of Zagreb, Faculty of Veterinary Medicine, Department of Hygiene, Technology and Food Safety, Zagreb, Croatia,

*corresponding author: Mladenka Vukšić, mvuksic@vef.hr

The aim of this study was to investigate the effects of freezing on the physical and chemical properties of beef from different breeds and sexes. As freezing is a widely used preservation method, understanding its influence on nutritional and technological quality is essential. A total of 32 samples of the surface hind leg muscle (m. gracilis) were analyzed, divided into two breed groups: Holstein and crossbreeds, each including eight male and eight female samples. Beef quality was evaluated through its physical, chemical, nutritional, and sensory characteristics, which directly influence consumer acceptance and market value.

Before and after freezing (12 months, -18 °C), the following parameters were measured: meat weight, CIE L*a*b* color, pH, temperature, water (ISO 1442), protein (ISO 937), fat (ISO 1443), and ash content (ISO 936). Normality of distribution was tested with Shapiro-Wilk test, differences between groups were tested with either Student t-test or Mann-Whitney U test, depending on data distribution. For testing differences between each variable before and after freezing t-test for dependent samples and Wilcoxon signed-rank test were used. P value p<0.05 was considered significant.

Results showed that all measured values remained within reference limits for beef, confirming its nutritional acceptability after freezing. Statistical analysis revealed significant differences in weight (all groups lost mass after defrosting, with male Holsteins being the leading loser), a* (10.15 – 10.7) and b* (12.67 – 12.85) color parameters, female crossbreeds showed the most significant lowering of a* and b* color values, and water (70.26% - 73.45%), most pronounced loss in crossbreeds (3.1%), and protein content (19.51% - 23.18%) where female crossbreeds lost the most and male crossbreeds the least protein. However, pH, temperature, and ash content did not show significant variations, indicating sample stability. These findings suggest that freezing does not substantially compromise beef quality, though certain quantitative changes may occur depending on the animal's breed and sex.

Keywords: beef, freezing, meat quality, physical properties, chemical composition

PRELIMINARY RESULTS ON THE PREVALENCE OF SALMONELLA SPP. SEROVARS IN CROATIA FOR 2025

Lucija Hlebić¹, Lovran Peinović¹, Andrea Humski¹, Antonela Bagarić², Sanja Duvnjak³, Maja Dopud³, Dora Tomašković¹

¹Laboratory for Food Microbiology, Department for Veterinary Public Health, Croatian Veterinary Institute, Zagreb, Croatia

²Laboratory for General Bacteriology and Mycology, Department for Bacteriology and Parasitology, Croatian Veterinary Institute, Zagreb, Croatia

³Laboratory for Bacterial Zoonoses and Molecular Diagnostics of Bacterial Diseases, Department for Bacteriology and Parasitology, Croatian Veterinary Institute, Zagreb, Croatia

*corresponding author: Dora Tomašković, stojevic@veinst.hr

Salmonellosis is one of the most common food-borne zoonoses, with meat and meat products being the primary sources of human infection. According to the latest EFSA and ECDC One Health Zoonoses Report for 2023, *Salmonella* is the second most frequent food-borne zoonosis in Europe. Fresh poultry meat and poultry products are particularly significant sources of contamination. While *Salmonella* Typhimurium and *Salmonella* Enteritidis are considered highly pathogenic, they are not the most prevalent serovars in poultry.

All strains were obtained from poultry samples. It should be emphasized that the reported serovar distribution, excluding *S. Infantis*, pertains to samples collected within a single food business operator, with each sample consisting of five individual units according to Regulation (EC) No 2073/2005 on microbiological criteria for food. The strains were serotyped using slide agglutination according to the Kauffmann-White-Le Minor scheme.

Preliminary data for 2025 show that a total of 185 strains were obtained from poultry meat, and the strains were subjected to serotyping. Of these, 77.84% (144/185) were identified as *Salmonella* *Infantis*, consistent with previous studies reporting this serovar as dominant in the Republic of Croatia. Other serovars identified in this study included *S. Newport* (3.78%, 7/185), *S. Cerro*, *S. Fillmore*, *S. Tennessee*, *S. Goldcoast* and *S. Dabou* (2.70%, 5/185), *S. Hadar*, (1.62%, 3/185), *S. Mbandaka* and *S. Agona*, (1.08%, 2/185), *S. Rissen* and *S. Newlands*, (0.54%, 1/185). Some of these serovars have been reported in previous literature, but to our knowledge, this study is the first confirmation of *S. Dabou*, *S. Cerro*, and *S. Newlands* in poultry meat within the Republic of Croatia.

These findings, along with previous outbreaks such as *S. Strathcona* associated with tomatoes, highlight the potential public health relevance of both common and rare *Salmonella* serovars, underscoring the need for continuous monitoring and risk assessment.

Keywords: *Salmonella* serovars, poultry meat, serotyping, prevalence

EPIDEMIOLOGY AND SEROTYPE DIVERSITY OF SALMONELLA SPP. IN POULTRY AND WILDLIFE: IMPLICATIONS FOR PUBLIC HEALTH IN BOSNIA AND HERZEGOVINA

Sajma Huremović^{1*}, Selma Kunić¹, Dejana Krneta²

¹Department of Microbiology, Public Institution Veterinary Institute of the Tuzla Canton, Tuzla, Bosnia and Herzegovina

²Department of Microbiology, Public Institution Veterinary Institute of the RS “Dr. Vaso Butozan”, Banja Luka, Bosnia and Herzegovina

*corresponding author: Sajma Huremović, sajma.huremovic@vetzavodtk.ba

Salmonellosis remains a major concern in poultry production due to its zoonotic potential and persistence on commercial broiler farms. The aims of this study were to isolate and identify *Salmonella* spp. serotypes from broiler farms in Bosnia and Herzegovina and to investigate the presence of serotypes of public health relevance.

The study included sampling of over-boot swabs (n = 1200) and fecal samples from heavy line broilers (n = 610), collected from multiple commercial broiler farms in Bosnia and Herzegovina during the primary production stage, three weeks before slaughter. Isolation and identification were performed following the ISO 6579-1:2017 method. For comparison, isolates originating from wildlife and other animals were included, comprising samples from wild duck (*Anas platyrhynchos*) (n = 10), pigeon (*Columba livia*) (n = 2), chinchilla (n = 1), and golden eagle (*Aquila chrysaetos*) (n = 1), collected in the Tuzla Canton and Banja Luka region. Out of 1810 samples, 36 were confirmed as *Salmonella* spp., with higher detection in over-boot swabs (2.3%) than in fecal samples (1.5%). *S. Enteritidis* was the predominant serotype, followed by *S. Typhimurium*, while other serotypes occurred sporadically. Isolates originating from wildlife were classified into serotypes or serogroups linked to poultry-associated *Salmonella*, indicating potential environmental reservoirs and possible indirect transmission pathways.

These findings confirm continuous circulation of *Salmonella* spp. in broiler production and underscore the importance of routine monitoring. Strengthened surveillance and targeted control measures are essential to reduce the prevalence of infection on farms and minimize the risk of transmission along the food chain.

Keywords: *Salmonella* spp., broilers, *S. Enteritidis*, *S. Typhimurium*, serotypes, surveillance, wildlife

CAMPYLOBACTER OCCURRENCE IN SEABIRDS DURING THE BREEDING SEASON IN CROATIA

Viktor Mašović^{1*}, Biljana Ječmenica², Louie Taylor³, Luka Jurinović¹

¹Laboratory for bacteriology, Poultry Centre, Croatian Veterinary Institute, Zagreb, Croatia

²Laboratory for bacteriology, Poultry Centre, Croatian Veterinary Institute, Zagreb, Croatia

³Institute of Ornithology, Croatian Academy of Sciences and Arts, Zagreb, Croatia

*corresponding author: Viktor Mašović, masovic@veinst.hr

Campylobacteriosis is the most common gastrointestinal bacterial disease in the European Union (EU) since 2005. Poultry is considered to be a natural reservoir for *Campylobacter* spp. Wild birds are also regarded as natural hosts for the growth of *Campylobacter* in their gastrointestinal tract, due to a combination of physiological and ecological factors important for *Campylobacter* growth, such as the low oxygen concentration in the avian gut and the optimal growth temperature of thermotolerant *Campylobacter* (42 °C). We tried/aimed to determine whether there is a connection between bird dietary ecology and *Campylobacter* occurrence in wild birds by conducting a study on four seabird groups during the breeding season. We tested cloacal swabs from three gull species (n=1639), one tern species (n=85), one shag species (n=67), and two shearwater species (n=349) for the presence of *C. jejuni* and *C. coli*, which are primarily responsible for campylobacteriosis in humans, and *C. lari*, which is more often isolated from sources associated with marine habitats like gulls or shellfish. This research was conducted across various breeding colonies of Croatia. Collected cloacal swabs were streaked on CampyFood Agar (CFA) agar plates. Molecular identification of *Campylobacter* species was done by Polymerase Chain Reaction (PCR). Total occurrence of *Campylobacter* spp. in these seabirds was 10.93%, with *C. jejuni* being the most detected species with 7.01% and most rarest detected was *C. coli* with 0.65%. The highest occurrence of *Campylobacter* spp. was found in gulls with 13.58%, followed by terns (11.76%) and shags (4.48%), while all the shearwater samples were negative. These findings appear to reflect the ecological and behavioural differences among the seabird groups. The study supports the idea that animals living in close association with humans may not only act as vectors of pathogens but are also more exposed to acquiring these pathogens themselves.

Keywords: gulls, wild birds, campylobacteriosis

**VETERINARY PUBLIC HEALTH
SESSION
POSTER PRESENTATION**

LOW-DOSE GAMMA RADIATION ALTERS PLASMA TOTAL LIPIDS IN BROILER CHICKENS EXPOSED *IN OVO*

Jadranka Pejaković Hlede^{1*}, Silvijo Vince², Ivona Žura Žaja¹, Ana Shek Vugrovečki¹, Stefani Fruk¹, Selim Pašić³, Marinko Vilić¹

¹*Unit of Physiology and Radiobiology, Faculty of Veterinary Medicine, University of Zagreb, Zagreb, Croatia*

²*Clinic for Obstetrics and Reproduction, Faculty of Veterinary Medicine, University of Zagreb, Zagreb, Croatia*

³*Unit of Physics, Faculty of Veterinary Medicine, University of Zagreb, Zagreb, Croatia*

Low doses of ionizing radiation can induce subtle biochemical and metabolic alterations, often associated with oxidative stress and adaptive cellular responses depending on developmental stage and species sensitivity. The purpose of this study was to investigate the effect of 0.3 Gy gamma radiation on plasma total lipids in broiler chickens hatched from eggs irradiated before incubation. A total of 700 fertilized broiler eggs (Ross 308) were randomly divided into two groups. The experimental group (n = 360) was irradiated with 0.3 Gy of gamma radiation from a cobalt-60 source one hour prior to incubation, while the control group (n = 340) was sham-irradiated. Blood samples were collected from 10 chicks per group on days 1, 3, 5, 7, 10, 20, 30 and 42 post-hatch. Plasma total lipids were determined spectrophotometrically using commercial reagents (Herbos Diagnostika d.o.o., Sisak, Croatia). Statistical evaluation was performed by Student's t-test ($P < 0.05$). Significant differences in plasma lipid concentrations were observed on days 5, 10 and 20 ($P < 0.05$). Lipid values were lower in irradiated chicks compared with controls on day 5 (1.62 vs. 1.91 g/L), while higher values were observed on day 10 (1.43 vs. 1.15 g/L) and day 20 (0.84 vs. 0.45 g/L). No significant differences were detected at other sampling days. Exposure of fertilized eggs to low-dose gamma radiation before incubation caused transient changes in plasma lipid concentrations of broiler chickens. These findings indicate that low-dose radiation may alter lipid metabolism during early post-hatch development, possibly reflecting an adaptive metabolic response.

Keywords: low-dose ionizing radiation; broiler chicken; plasma total lipids; gamma radiation

THE ASSESSMENT OF ANTE MORTEM PROCEDURES IN THE CATTLE SLAUGHTERHOUSE RELEVANT TO ANIMAL WELFARE

Laura Johanna Leisti¹, Mladenka Vukšić^{2*}, Tomislav Mikuš²

¹City control veterinarian, Savonlinna, Finland

²Department of Hygiene, Technology and Food Safety, University of Zagreb, Faculty of Veterinary Medicine, Zagreb, Croatia

*corresponding author: Mladenka Vukšić, mvuksic@vef.hr

Exceeding benchmark levels of cattle showing visible impairments upon arrival at slaughterhouses affects meat quality, consumer confidence, and compliance with EU welfare standards. This issue is especially relevant in Croatia, where cattle originate from various countries and are exposed to differing management systems, transport distances, and handling conditions before slaughter.

A form adapted from the Welfare Quality® (2009) protocol was used over one week on three separate days in a Croatian slaughterhouse. The study included 295 animals, Holstein and beef breeds. Observations in the lairage and corridor lasted 15–30 minutes and focused on coughing, nasal discharge, lameness, limb swelling, and visible lesions. Statistical analyses were performed using Python (v3.10) and Microsoft Excel (Office 365), with significance set at 0.05.

A total of 45 animals (15.25%; 95% CI: 11.6–19.8%) showed *ante mortem* changes. Lameness was observed in 14 (4.7%), visible lesions in 17 (6.0%) including broken horns, hairless patches, tumors, a punctured eye, and one case of crossed eyes. Two animals (0.6%) coughed, one (0.3%) had a swollen limb, and 11 (3.7%) showed nasal discharge—10 bloody, one white. The difference from the expected 2% benchmark was statistically significant ($p < 0.001$).

These findings highlight the need to integrate *ante* and *post mortem* data, as recommended by the Welfare Quality® framework, to identify causes of welfare impairments and develop targeted interventions.

Keywords: *ante mortem*, cattle, slaughterhouse, Welfare Quality®

GENERAL POSTER SESSION

CHEMICAL ANALYSES OF NEUROMELANIN ACCUMULATION IN ANIMAL MODELS – A REVIEW

Doroteja Hunjadi^{1*}, Tomislav Mašek², Kristina Starčević³

¹student, Faculty of Veterinary Medicine, University of Zagreb, Zagreb, Croatia

²Department of Animal Nutrition and Dietetics, Faculty of Veterinary Medicine, University of Zagreb, Zagreb, Croatia

³Department of Chemistry and Biochemistry, Faculty of Veterinary Medicine, University of Zagreb, Zagreb, Croatia

**corresponding author: Doroteja Hunjadi, dhunjadi@vef.hr*

Melanin is a pigment present in the skin that determines skin colour, while in the brain it is macroscopically visible as neuromelanin (NM), produced in catecholaminergic neurons, mainly in the substantia nigra (SN) and locus coeruleus. NM binds iron and can act as protective or damaging substance. With ageing, iron accumulation in the SN increases, whereas in some neurodegenerative diseases, the SN appears less pigmented. Rodents naturally accumulate little NM, so transgenic mice expressing human tyrosinase have been developed to model age-dependent NM accumulation. Larger mammals, which naturally possess NM, represent valuable models for studying NM. However, structural heterogeneity of NM differ between species, posing significant analytical challenges and combination of different techniques.

NM is analysed using a combination of chemical and structural analytical techniques. Spectroscopic methods provide insights in NM functional groups, metal binding and redox properties. Infrared spectroscopy identifies phenolic and indolic groups involved in iron coordination, while electron paramagnetic resonance detects stable free radicals. Furthermore, Mössbauer spectroscopy clarifies the oxidation state of bound iron. Additional techniques, such as UV-visible, Raman, and X-ray photoelectron spectroscopy give insights into NM's electronic structure and metal coordination. Also, more advanced methodology, like electron microscopy along with energy-dispersive X-ray spectroscopy, enable visualization of NM granules and give more estimated insight of their metal content. Finally, high-performance liquid chromatography after chemical degradation identifies NM monomers.

Due to its chemical complexity, metal-binding properties and species-specific heterogeneity, NM remains challenging to study. For that reason, combining analytical techniques with suitable animal models is essential for understanding its structure, biological function and role in ageing and neurodegeneration.

Keywords: neuromelanin, neurodegeneration, chemical analyses, animal models

ISCHAEMIC STROKE INDUCES REACTIVE ASTROGLIOSIS IN TRANSPLANTED NEURAL STEM CELLS

Sandra Kunštek¹, Tomislav Hader², Ante Plećaš³, Ivan Alić^{3*}

¹Department of Pathophysiology, Faculty of Veterinary Medicine, University of Zagreb, Zagreb, Croatia, ²Faculty of Veterinary Medicine, University of Zagreb, Zagreb, Croatia, ³Department of Anatomy, Histology and Embryology, Faculty of Veterinary Medicine, University of Zagreb, Zagreb, Croatia

**corresponding author: Ivan Alić, ialic@vef.hr*

Stroke is a medical emergency that happens when something prevents your brain from getting enough blood flow. It is a severe neurological disorder that can occur in either haemorrhagic or ischemic form. Neural Stem Cells (NSCs) represent a heterogeneous population capable of differentiating into neurons and glia-cells. In this study, we induced ischemic stroke in mice by transient occlusion of the middle cerebral artery, and 24 hours after surgery, NSCs were injected into the mouse brain. In this study, two mouse strains were used – wild type and transgenic B6.Cg-Tg(Thy1-YFP)16Jrs/J (Thy1 YFP-16), both kept on the same genetic background. In total, 15 adult animals were used: five pregnant females for NSCs isolation, five males for stroke induction, as well as an additional five males for the control group. Thy1 YFP-16 cells express yellow fluorescent protein (YFP) in approximately 22% of neurons under the control of the Thy1 promoter. The main goal of the study was to assess the fate of transplanted cells four weeks after transplantation in both groups. Our findings revealed significant differences in the number of TUBB3-positive neurons and GFAP-positive astrocytes between the groups. Moreover, the control group showed a significantly higher proportion of Thy1-YFP cells. Pearson's coefficient showed colocalization between Thy1-YFP and TUBB3-positive neurons, while there was no colocalization between Thy1-YFP and GFAP-positive astrocytes. Based on these results, we can conclude that stroke induce astrogliosis in both, host tissue and graft. Glia cells were bigger with more branches and more confluent in animals affected by stroke.

Keywords: Stroke, Neural Stem Cells, Astrogliosis, Thy1-YFP

PROJECT SESSION
ORAL PRESENTATIONS

MIGRATION OF GABAERGIC NEURONS: INVESTIGATION OF BRAIN DEVELOPMENT IN DOWN SYNDROME

Ante Plećaš¹, Ana Družeta¹, Sandra Kunštek², Ivan Alić¹

¹*Department of Anatomy, Histology and Embryology, Faculty of Veterinary Medicine University of Zagreb, Croatia*

²*Department of Pathophysiology, Faculty of Veterinary Medicine, University of Zagreb, Croatia*

**corresponding author: aplecas@vef.hr*

Down syndrome (DS) caused by trisomy of chromosome 21, which can occur as complete trisomy 21 (T21), partial trisomy 21 (pT21), or mosaicism is the most common congenital cause of intellectual disability and the most common genetic cause of early-onset Alzheimer's disease (AD). In addition, individuals with DS have more behavioural problems and psychiatric disorders compared to the general population. Dual diagnosis of DS and autism is also very common. Cortico-striatal projections are crucial for regulating motivated behaviour, and their dysfunction underlies many neuropsychiatric disorders characteristic for DS. Adris Foundation provided funding for the period November 2025 –October 2026 to analyse GABAergic interneurons in an isogenic model. In the first step, neurons will be analysed in 2D, and the proportions of individual interneuron subpopulations will be compared between disomy 21 (D21) and trisomy (T21). Additionally, the morphology of individual interneurons and synaptogenesis will be examined. Following the completion of the 2D analysis, the same analysis on cortico-striatal assembloids will be performed. Furthermore, cortico-striatal projections and synaptic connectivity between different brain regions will be analysed, with a particular focus on interneuron migration. The main aim of this study is to induce isogenic Neural Stem Cells (NSCs) from iPSCs derived from an individual who is a structural mosaic for DS, and differentiate them into isogenic GABAergic neurons in a 2D culture. Additionally, the same iPSCs will be used to generate assembloids grown in a 3D. The composition of the assembloids (neuronal subpopulations) will be compared, with emphasis on the population of GABAergic interneurons, which *in vivo* migrate into the cortex and enable the establishment of proper neuronal networks and synapse formation-processes disrupted in DS. This project will result in the establishment of assembloids technology for the first time in Croatia and will provide valuable insight into key processes occurring during nervous system development, which later in life contribute to various neurodevelopmental and neuropsychiatric disorders in DS. By gaining a deeper understanding of the causes underlying these disorders, we may help millions of individuals with this chromosomal condition as well as their families.

Keywords: Down syndrome, iPSCs, GABA, neurons, assembloids

HUMAN CORTICO-MOTOR ASSEMBLOIDS REVEAL THE ROLE OF THE DYRK1A GENE IN DOWN SYNDROME

Ante Plećaš¹, Sandra Kunštek², Matija Horaček³, Petra Šoštarić Mužić⁴, Ana Družeta¹, Anna Titova¹, Gillian Gough⁵, Ivan Alić¹

¹Department of Anatomy, Histology and Embryology, Faculty of Veterinary Medicine University of Zagreb, Croatia

²Department of Pathophysiology, Faculty of Veterinary Medicine, University of Zagreb, Croatia

³Institute of Pathology, School of Medicine, University of Zagreb, Croatia

⁴Department of Neuroscience, Karolinska Institutet, Stockholm, Sweden

⁵NUS Yong Loo Lin School of Medicine, Singapore, Singapore.

**corresponding author: ialic@vef.hr*

Down syndrome (DS) is the most common congenital cause of intellectual disability and the most common genetic cause of early-onset Alzheimer's disease (AD). This project, financed by the Croatian Science Foundation, is based on strong preliminary observations of cell-intrinsic changes caused by trisomy of chromosome 21 (T21) in human induced pluripotent stem cell (iPSC)-derived neurons and T21 foetal tissues. These changes affect neurite development, synaptogenesis, and plasticity, contributing to electrophysiological abnormalities. As DYRK1A is one of the key genes in the Down Syndrome Critical Region, this project will focus on DYRK1A as a crucial gene for neuronal cell morphology, synaptic formation and maturation. Our hypothesis is: "Two copies of the DYRK1A gene are both necessary and sufficient for normal neuronal morphology and the formation of neuromuscular junctions (NMJs). Using iPSC models with isogenic and partial T21, as well as CRISPR-edited clones, we will analyse the role of DYRK1A in the formation and function of NMJs in both 2D (neurons-Schwann cells-myotubes) and 3D (cortico-motor assembloids) models. Our data will be validated using histological and molecular methods. After obtaining results using histological and molecular methods, the electrophysiological analyses will be performed. The in vitro data will be compared with a large collection of tissues from a human brain bank. Finally, the results will be further validated using Dp1Tyb mice, which carry three copies of all 148 genes found on human chromosome 21. The findings from this project will clarify the role of DYRK1A in DS and its impact on neuronal development and function.

Keywords: Down syndrome, iPSCs, DYRK1A, neuromuscular junctions, assembloids

GENES OF DOWN SYNDROME CRITICAL REGION CAUSING ABERRANT NEURONAL MORPHOLOGY

Ante Plećaš¹, Sandra Kunštek², Ana Družeta¹, Anna Titova¹, Ivan Alić¹

¹*Department of Anatomy, Histology and Embryology, Faculty of Veterinary Medicine, University of Zagreb, Croatia*

²*Department of Pathophysiology, Faculty of Veterinary Medicine, University of Zagreb, Croatia*

**corresponding author: ialic@vef.hr*

Down syndrome (DS) is the most common congenital cause of intellectual disability and the commonest genetic cause of early onset Alzheimer's disease (AD). This study, financed by International Centre for Genetic Engineering and Biotechnology (ICGEB), is based on firm preliminary observations of cell-intrinsic changes caused by trisomy 21 (T21) in human iPSCs derived neurons and in T21 foetal brains, focusing on neurite development, synaptogenesis and plasticity, which underline the electrophysiological abnormalities. In post-natal human brain, the re-polarisation of axons and re-wiring of dendrito-synaptic compartments are plastic and could be therapeutically targeted. Our hypothesis is that one or more over-expressed genes from chromosome 21 affect neurofilament regulation and morphological abnormalities of neurons in Down Syndrome. Using iPSCs models of partial T21 (pT21), as well as CRISPR-edited isogenic iPSCs clones we aim to genetically assign specific cellular phenotypes to specific region/gene on chromosome 21, in neurons grown in 2D, 3D cultures, organoids and assembloids. We will analyse dendritic spines, mitochondrial morphology and distribution in dendrites, presynaptic and branching sites, and their axonal transport using fluorescence imaging and traditional histological methods. The observed morphological changes *in vitro* will be tested for reproducibility on the large collection of human foetal and adult brains. The main purpose of our study is to describe the influence of particular genes on cell morphology and neuropathology in DS.

Keywords: Down syndrome, iPSCs, Down Syndrome Critical Region, assembloids

LIGHTING THE WAY TOWARDS IN SITU OSTEOCHONDRAL REGENERATION THROUGH MICROEXTRUSION AND FILAMENTED LIGHT BIOPRINTING (LUMINATE)

Dražen Matičić¹, Petar Kostešić¹, Mirta Vučković¹, Valentina Kos¹

¹University of Zagreb, Faculty of Veterinary Medicine, 10000 Zagreb, Croatia

*corresponding author: drmaticic@vef.unizg.hr

Traumatic osteochondral injuries of diarthrodial joints such as the knee lead to pain, loss of function, significantly increased risk of post-traumatic osteoarthritis (PTOA) and associated comorbidities. Existing treatment options, including acellular grafts and cell-based therapies are costly and often of limited availability, frequently resulting in total joint arthroplasty to restore mobility and reduce pain. In young and physically active patients, however, implant durability is limited and revision rates are unacceptably high, indicating a future surge in revision surgeries as implants fail over time.

The LUMINATE project (www.luminateproject.eu) introduces a personalized, one-stage regenerative strategy aimed at treating large osteochondral defects while preventing PTOA progression and avoiding invasive and expensive arthroplasty procedures. For the purposes of this project, a next-generation in situ bioprinting tool that integrates micro-extrusion, filamented light, and jet-printing technologies, EndoFLight is being developed. This will enable the precise deposition of photosensitive biomaterials containing autologous patient cells, directly at the injury site.

Filamented light allows rapid fabrication of highly organized scaffolds with exceptional cell-guidance properties. When combined with micro-extrusion and jet printing in an arthroscopic setting, EndoFLight enables simultaneous delivery of multiple biomaterials, biomolecules, and cell types, with light-assisted crosslinking of complex structures directly *in vivo* through a minimally invasive procedure. The complete workflow will be validated in a human-relevant large-animal model to support clinical translation. Project outcomes will be exploited through market analysis, spin-off creation, and regulatory assessment of all bioprinting system components.

LIFE WILD WOLF: A LONG-TERM CONSERVATION OF WOLVES IN HUMAN DOMINATED LANDSCAPES OF EUROPE – UNDERSTANDING WOLF - DOG INTERACTIONS

Josip Kusak^{1*}, Dario Hipolito¹, Krešimir Severin¹, Maja Popović¹, Daniel Špoljarić¹, Lana Pađen¹, Magdalena Palić¹, Neška Vukšić Končevski³, Andrea Solić^{1,2}

¹ Faculty of Veterinary Medicine, University of Zagreb, Croatia

² Croatian Hunters Association

³ Auric Nature d.o.o.

*corresponding author: kusak@vef.hr

The LIFE WILD WOLF project aims to keep wolves wild in human-dominated landscapes and reduce conflicts across Europe. In Croatia, the focus was on Dalmatia, where wolf–livestock and wolf–dog interactions are frequent. Activities included GPS and camera-trap monitoring, genetic sampling, and systematic reporting of wolf encounters and dog damages. Social interventions included workshops, training for damage inspectors, and the creation of the Dalmatian stakeholder platform. More than 150 dog protection systems were deployed, resulting in decreased wolf–dog damages. Genetic analysis of 282 samples confirmed no first-generation wolf–dog hybrids. A pilot program for protective vests for hunting dogs showed high acceptance and reduced injuries from wolves and wild boars. The Dalmatian platform improved communication among hunters, farmers, and authorities, enabling rapid response and attractant removal. International guidelines were developed on how to behave when wolves appear near settlements, remove attractants, keep pets leashed, avoid feeding wildlife, and report sightings. If a wolf is close, stay calm, speak loudly, and back away slowly. Authorities should use deterrents or capture wolves only if bold behavior persists. Integrated ecological monitoring, preventive measures, and stakeholder engagement significantly reduce conflicts. The LIFE WILD WOLF project offers a replicable model for large carnivore conservation in Europe. It is conducted from January 2023 to August 2027., and is cofounded by the European Union, Environmental Protection and Energy Efficiency Fund of Croatia, and Bernd Thies Foundation.

Keywords: wolf conservation, bold behaviour, coexistence, Dalmatia, livestock protection

UNIC VIP PROJECT EQUINE REPRODUCTION- EDUCATIONAL AND EXPERT COLLABORATION BETWEEN CROATIA AND BELGIUM 2026-2028

Nikica Prvanović Babić^{1*}, Juraj Grizelj¹, Stefan Deleuze²

¹Faculty of Veterinary Medicine University of Zagreb, Croatia

² Faculty of veterinary medicine, University in Liege, Belgium

**corresponding author: nikica@vef.unizg.hr*

UNIC is a European Universities alliance, connecting ten European universities in cities encountering post-industrial transition. The partners work collaboratively on shared teaching and learning innovation, student and staff mobility, city engagement and more. The UNIC university partners are Erasmus University Rotterdam, Koç University Istanbul, University of Deusto in Bilbao, University of Liège, Ruhr University Bochum, University of Oulu, University of Zagreb, University of Lodz, Malmö University, and University College Cork. The participation in this bilateral project funded by VIP UNIC fund, will be offered on voluntary base to the 5th year students of both faculties (Zagreb and Liege) who attend Equine Medicine course. Students who decide to take part in activity will participate in the program which will last 7 weeks, each week 2h of classes for each group (in total each group will attend 14h of virtual exchange in total). In total, we will have 30 students from both universities (15 from Zagreb + 15 from Liege) that will be divided in 4 groups (2 groups of 7 and 8 students from Zagreb and the same composition of groups in Liege). Project starts at 1th March 2026 and lasts till 15 July 2028. Virtual exchange will last for 7 weeks, each week 2hours session (in total 14 h of virtual exchange for each participating student) using Teams and Zoom platforms. Students will get all needed materials and topics in advance to get ready for each virtual session. Their responsibility and motivation will be highly appreciated. The idea is to exchange examples of good practice and protocols to create and increase challenge-based learning database used by Croatian and Belgian students of final year of veterinary medicine. Both side teachers (2 teachers from each side need to be provided) are responsible to motivate, monitor and encourage their students to take part as active as possible in virtual classroom. Croatian group would be consisted of motivated students of Equine Medicine course from both Croatian and English programme. Teachers are also responsible to provide learning materials and real time cases that will be the base for the virtual exchange. Teachers will also lead the classes, encourage and guide discussions, and create the students' groups (groups are consisted of 7/8 students) and time schedule that will be created before the start of the semester. Students who have earned the most points by actively participating in the practicals of activity/project will have the opportunity for physical in site visit of Liege School. During visit of Liege school, guided by the teachers at both universities students will gain direct and precious experience of well established equine reproduction unit. In the same time teachers will also have opportunity to openly discuss the virtual exchange experience and to compare the results of the students who attended virtual exchange with those who didn't.

Keywords: virtual university, challenge based learning, equine reproduction, collaboration, Zagreb, Liege

DEVELOPMENT OF A PROTOTYPE IMMUNOCHROMATOGRAPHIC TEST FOR THE DETECTION OF LACTOFERRIN AND CATHELICIDIN IN COW'S MILK

Dominik Priščan¹, Josipa Kuleš², Renata Barić Rafaj², Miroslav Benić³, Blanka Beer Ljubić¹, Tihana Lenac Roviš⁴, Berislav Lisnić⁴, Jose Ceron⁵, Alberto Munoz Prieto⁵, Dina Rešetar Maslov¹, Goran Bačić⁶, Nino Maćešić⁶, Tamara Aleksandrov Fabijanić⁷, Matej Horvat⁷, Lada Radin⁸, Vladimir Mrljak^{1*}

¹Clinic for Internal Diseases, Faculty of Veterinary Medicine, University of Zagreb, Croatia

²Department of Chemistry and Biochemistry, Faculty of Veterinary Medicine, University of Zagreb, Croatia

³Croatia Veterinary Institute, Zagreb, Croatia

⁴Center for Proteomics, Faculty of Medicine, University of Rijeka, Croatia

⁵University of Murcia, Spain

⁶Clinic for Reproduction and Obstetrics, Faculty of Veterinary Medicine, University of Zagreb, Croatia

⁷Center of Technology Transfer, Zagreb, Croatia

⁸EU funds & Technology Transfer Office, Faculty of Veterinary Medicine, University of Zagreb, Zagreb, Croatia

**corresponding author: vmrljak@vef.hr*

Inflammation of the mammary gland (mastitis) is the most common infectious disease in dairy cows and represents the greatest threat to the health and productivity of dairy herds. Inflammatory changes may induce systemic symptoms; however, clinical signs can be hidden while the udder and milk appearing normal, which constitutes a major problem because the prevalence of this condition within a herd is 2 to 20 times higher than that of the clinical form. Current methods for accurate and objective determination of somatic cell count require laboratory conditions, making these approaches time-consuming and financially demanding. All of the above has resulted in the need to develop a rapid test for the early detection of mammary gland inflammation.

The objectives of the project are: (1) to examine the specificity of the biomarker–antibody reaction; (2) early development of a low-level rapid test prototype in strip format as proof of concept; and (3) laboratory testing and validation of a functional prototype under laboratory conditions.

In previous studies, the first phase of rapid test development was conducted, during which proteomics was used to identify potential biomarkers of subclinical mastitis. Antibodies against lactoferrin and cathelicidin-1 were developed and characterized.

Selected antibodies against lactoferrin and cathelicidin-1 will be evaluated using ELISA, Western blot and Universal Lateral Flow kit. Initial laboratory testing will be performed to assess the diagnostic sensitivity, specificity, accuracy, and reaction time of the prototype. The low-level prototype will be tested in milk under laboratory conditions to determine its functionality, efficiency, and reliability.

The development of an innovative immunochromatographic test for the early detection of mastitis in dairy cows is expected to enable rapid, accurate, and simple on-farm diagnosis of subclinical mastitis, thereby replacing slow and costly laboratory-based methods.

Keywords: subclinical mastitis, biomarker, lactoferrin, cathelicidin-1, cowside test

OMICS APPROACH AND DEEP PHENOTYPING IN DISCOVERING NOVEL BIOMARKERS FROM EXOSOMES IN CARDIAC DISEASES OF DOGS

Vladimir Mrljak^{1*}, Marin Torti¹, Katarina Marjanović¹, Martina Crnogaj¹, Ines Jović¹, Josipa Kuleš², Renata Barić Rafaj², Gordana Gregurić Gračner³, Damjan Gračner¹, Jose Ceron⁴, Dina Rešetar Maslov¹

¹Clinic for Internal Diseases, Faculty of Veterinary Medicine, University of Zagreb, Croatia

²Department of Chemistry and Biochemistry, Faculty of Veterinary Medicine, University of Zagreb, Zagreb, Croatia

³Department of Animal Hygiene, Behaviour and Welfare, Faculty of Veterinary Medicine, University of Zagreb, Croatia

⁴Interdisciplinary Laboratory of Clinical Analysis (Interlab-UMU), Regional Campus of International Excellence 'Campus Mare Nostrum' University of Murcia, Murcia, Spain

**corresponding author: vmrljak@vef.hr*

Myxomatous mitral valve disease (MMVD) is the most common acquired cardiac disease in dogs and the leading cause of cardiovascular morbidity and mortality. Diagnosis is based on clinical signs and imaging modalities; however, the identification of the disease in its asymptomatic stage remains challenging. Therefore, the identification of early diagnostic biomarkers is of critical importance. Advances in molecular cardiology have demonstrated that exosomes may serve as potential biomarkers in cardiovascular diseases. Exosomes, small vesicles involved in intercellular communication, carry biologically active molecules (proteins, lipids, metabolites, and nucleic acids) and reflect both physiological and pathological states. The development of mass spectrometry-based techniques in proteomics and metabolomics has opened new opportunities for the discovery of novel exosomal biomarkers in canine cardiac diseases. Within the scope of our project, relative protein quantification using tandem mass tag (TMT) labeling will be applied, followed by untargeted metabolomic analysis and targeted metabolomics using a laboratory-based metabolite quantification kit.

The aim of our project is to investigate the molecular composition of exosomes isolated from the urine of dogs at different stages of MMVD and from healthy dogs, with the goal of identifying novel biomarkers. By analyzing the exosomal proteome and metabolome, we seek to identify early and discriminatory biomarkers, explore molecular interactions, and improve the diagnostic approach to MMVD. The expected results may contribute to earlier diagnosis and improved treatment outcomes in dogs affected by this disease.

Keywords: proteomics, metabolomics, diseases of the heart, exosomes, urine, dog

MULTI-OMICS APPROACH IN DISCOVERING NOVEL BIOMARKERS OF EXTRACELLULAR VESICLES IN CARDIAC DISEASE OF DOGS

Dominik Prišćan¹, Marin Torti¹, Martina Crnogaj¹, Elizabeta Pongrac¹, Ines Jović¹, Josipa Kuleš², Renata Barić Rafaj², Blanka Beer Ljubić¹, Iva Šmit¹, Damjan Gračner¹, Jose Ceron³, Alberto Munoz Prieto³, Dina Rešetar Maslov¹, Vladimir Mrljak^{1*}

¹Clinic for Internal Diseases, Faculty of Veterinary Medicine, University of Zagreb, Croatia

²Department of Chemistry and Biochemistry, Faculty of Veterinary Medicine, University of Zagreb, Croatia

³Interdisciplinary Laboratory of Clinical Pathology, Interlab-UMU, Campus of Excellence Mare Nostrum University of Murcia, Murcia, Spain

**corresponding author: vmrljak@vef.hr*

Myxomatous mitral valve disease (MMVD) is the most prevalent acquired heart disease and one of the most important causes of left-sided heart morbidity in dogs. Currently, diagnosis of MMVD is primarily based on clinical signs and imaging. Without clinical signs or imaging, it is hard to recognize the development of the disease, which is especially important in asymptomatic phase. The importance of defining early diagnostic biomarkers of MMVD in dogs is of utmost significance. Recent developments in molecular cardiology have shown that extracellular vesicles

(EVs) can serve as potential biomarkers in cardiovascular diseases. Circulating EVs have a key role as bioactive mediators of intercellular communications and promising applications in

diagnosis and disease monitoring. The development of mass spectrometry-based techniques, like in proteomics and metabolomics, allows a multi-omics approach to discovering novel biomarkers of EVs in the cardiac disease of dogs. Our project employs a multi-omics approach to investigate biomarkers of circulating EVs isolated from dogs with different stages of MMVD development. We hypothesize that EVs from serum reflect physiological and pathophysiological processes, leading to distinct molecular cargo (proteome and metabolome) differences between EVs of dogs diagnosed with MMVD and healthy dogs. Our goals include the isolation and characterization EVs from serum of dogs with different stages of MMVD and healthy dogs, characterization of EV using proteomics and metabolomics, comparing EV proteomes and metabolomes of dogs with different stages of MMVD versus healthy dogs' EVs, discovering early-stage diagnostic EV biomarkers in dogs with MMVD by integrated multi-omics approach, identifying involved molecular signaling pathways, in order to clarify the pathophysiological processes of disease development and investigation of interactions between proteins and metabolites, improving the diagnostics of MMVD and longer patient survival.

Keywords: proteomics, metabolomics, diseases of the heart, extracellular vesicles, dog

SEPSIS BIOMARKER IDENTIFICATION IN EXTRACELLULAR VESICLES OF DOGS

Lorena Franco Martínez¹, Isabel Barranco², Vladimir Mrljak^{1*}

¹Clinic for Internal Diseases, Faculty of Veterinary Medicine, University of Zagreb, Croatia

²Department of Medicine and Animal Surgery, Veterinary Science, University of Murcia, Murcia, Spain

**corresponding author: vmrljak@vef.hr*

Sepsis is one of the leading causes of death in hospitals due to its quick progresses and the lack of reliable tools to detect it early. This project seeks to investigate the potential of extracellular vesicles (EVs) as a new source of biomarkers for sepsis. EVs are tiny particles naturally released by cells for intercellular communication and they carry a wide range of molecules. Previous research suggests EVs may be particularly useful for detecting sepsis — but there are still many challenges to overcome.

The project will study EVs in two readily accessible biofluids, serum and saliva, from healthy and septic dogs to detect differences that could lead to new sepsis biomarkers. Dogs share many physiological and anatomical similarities with humans, and they can develop diseases in ways that closely resemble human conditions. Specifically, pyometra is considered a naturally occurring model of sepsis. The first phase consists of identifying the best technique to isolate EVs in these samples, which had not been studied before. Later, the possible differences in EV characterization (morphology, concentration and size), general biochemical analysis, and advanced omics techniques (proteomics and metabolomics), will be compared across three groups (healthy controls, animals with sepsis, and animals with non-septic inflammation) with the goal of discovering biomarkers that indicate the presence or progression of sepsis.

As of February 2026, the project is at its tenth month. Three different EVs isolation techniques have been successfully optimized and applied in canine samples. Size-Exclusion Chromatography was selected by its higher purity (i.e. lower non-EV particles), providing more accurate results for the subsequent characterization, biochemical and omics analyses.

In summary, this multidisciplinary project aims to open new doors in early diagnosis and disease monitoring, improving the lives of both people and animals alike.

Keywords: Extracellular vesicles, Sepsis, Infection, Biomarkers, Dogs, Saliva

BEST PRACTICES AND INNOVATIONS FOR SUSTAINABLE BEEKEEPING (B-THENET PROJECT)

Ivana Tlak Gajger

Faculty of Veterinary Medicine, University of Zagreb, Croatia

e-mail: itlak@vef.unizg.hr

The B-THENET Thematic Network is one of the first coordinated European initiatives that systematically connects best practices and innovations in beekeeping, intending to modernise the sector and strengthen its sustainability. It is built on a multi-actor approach in which beekeepers, advisors, researchers, veterinarians, policymakers and other stakeholders jointly collect, classify and select practices or biosecurity measures that are effective, ready to use, and aligned with real needs in the field. In this way, the project creates a bridge between research results, practical experience and digital tools, with a strong focus on knowledge that can be directly applied in the apiary. At the core of B-THENET are four interconnected platforms. “Practices” and “R&I” (research and innovations) are used to gather and structure best practices and research outputs, “Exchange” supports their sharing, adaptation and validation, while the long-term “Repository” stores validated practices in the form of attractive audiovisual materials in 15 European languages. Only those solutions that meet beekeepers’ and vets’ needs, have demonstrated effectiveness and are ready for implementation are selected, taking into account national and regional differences in climate, equipment, bee genetics, disease pressure and production scale. This process supports the development of a concept of best beekeeping practices that is both scientifically grounded and field-tested. Within this framework, 13 National B-THENET Centres play a key role in translating European knowledge to the local level and, at the same time, feeding local innovations back into the European knowledge base. These centres organise advisory activities, training and events, participate in the validation of practices, and contribute to the preparation of an EU Manual of Best Practices and Guidelines for Beekeeping Vets Advisors, thereby supporting more coherent standards for sustainable beekeeping across Europe. The B-THENET Centre Croatia is responsible for identifying, selecting and adapting best practices and biosecurity measures to the specific conditions of Croatian beekeeping and for presenting them in a national version of the platform in the Croatian language. In doing so, the Faculty of Veterinary Medicine University of Zagreb actively contributes to Project (HORIZON-CL6-2021-GOVERNANCE-01) and to the shaping of a European knowledge network while ensuring that domestic stakeholders in the apiculture sector gain access to reliable, practical and locally relevant solutions for sustainable beekeeping.

Keywords: sustainable beekeeping; best practices; biosecurity measures; innovations; multi-actor approach; knowledge exchange; digital platforms; B-THENET Center Croatia; Faculty of Veterinary Medicine; University of Zagreb

B-THENET project is financed by the Horizon Europe Research and Innovation Framework Programme under Grant Agreement No 101059812.

PROJECT SESSION
POSTER PRESENTATIONS

AVIATOR - AVIAN RESILIENCE AND ADAPTATION THROUGH AWARENESS, MONITORING, TREATMENT, AND OUTREACH FOR RAPTORS

Kristina Popović¹, Dražen Đuričić², Maja Belić³, Franjo Martinković⁴, Marija Martinko Ivanov⁵, Bolesław Stociński⁵, Maja Lukač^{2*}

¹*Student, Faculty of Veterinary Medicine University of Zagreb, Croatia*

²*Department of Poultry Diseases with Clinic, Faculty of Veterinary Medicine University of Zagreb, Croatia*

³*Department of Pathophysiology, Faculty of Veterinary Medicine University of Zagreb, Croatia*

⁴*Department of Parasitology and Invasive Diseases, Faculty of Veterinary Medicine University of Zagreb, Croatia*

⁵*Association BIOM, Zagreb, Croatia*

**corresponding author: maja.lukac@vef.unizg.hr*

The Danube Region encompasses diverse ecosystems that provide critical habitats for numerous avian species, particularly birds of prey, which are essential for maintaining trophic balance and ecosystem stability. Raptors are increasingly threatened by anthropogenic pressures and climate change, which exacerbate the spread of infectious and parasitic diseases and may trigger cascading ecological effects, including biodiversity loss and habitat alteration.

The AVIATOR project aims to enhance the resilience, adaptive capacity, and long-term conservation of raptor populations through a coordinated transnational approach, with four primary goals: awareness, to increase understanding of raptor ecology and threats; monitoring, to systematically assess population dynamics and health status; treatment, to develop, test, and implement protective measures including vaccination and vector control; and outreach, to actively engage stakeholders and facilitate knowledge exchange for evidence-based conservation and policy alignment.

Key activities include pilot studies assessing disease risks, testing vaccination efficacy against West Nile Virus, and evaluating vector control strategies; development of a digital platform for knowledge sharing, monitoring, and coordination; formulation of Local Action Plans integrating stakeholder engagement; and creation of a Joint Monitoring, Conservation, and Control Strategy with actionable measures to guide interventions and inform public policy.

Ongoing results include the implementation of these plans and strategies across ten regions, extensive multi-level stakeholder cooperation, and the progressive evaluation of innovative conservation solutions, such as vaccination, vector control, and the Birds of Prey Platform, to enable future scaling and policy integration across the Danube Region. These efforts collectively aim to safeguard endangered raptor populations while maintaining essential ecosystem services. This project is supported by the Interreg Danube Region Programme co-funded by the European Union. The total project budget amounts to €2,164,252, with €1,731,402 provided through Interreg funding. The project duration runs from April 2025 to October 2027.

Keywords: birds of prey, raptors, Danube region, conservation

INDUCTION AND PERSISTENCE OF VIABLE BUT NON-CULTURABLE (VBNC) YERSINIA ENTEROCOLITICA 4/O:3 IN PORK – PRESENTATION OF THE PROJECT

Nevijo Zdolec^{1*}, Marta Kiš¹, Mladenka Vukšić¹, Vesna Mojčec Perko², Vladimir Farkaš³

¹*Department of Hygiene, Technology and Food Safety, Faculty of Veterinary Medicine, University of Zagreb, Croatia*

²*Department of Microbiology and Infectious Diseases with Clinic, Faculty of Veterinary Medicine, University of Zagreb, Croatia*

³*Division of Animal Physiology, Faculty of Science, University of Zagreb, Croatia*

**corresponding author: nzdolec@vef.unizg.hr*

According to the latest official European reports, yersiniosis is the fourth most commonly reported zoonosis in the EU. It is caused by *Yersinia enterocolitica*, and cases in humans are often linked to the consumption of undercooked pork. With the aim of reducing the incidence of this pathogen in the pork production chain, research was conducted into the potential use of organic acids for decontaminating pork meat.

The above-mentioned studies raised questions whether the observed differences in the susceptibility of *Y. enterocolitica* 4/O:3 to acidic conditions occurred due to the "hibernating" VBNC (Viable but Non-Culturable) state. Therefore, this project (HRZZ-IP-2025-02-7300), supported by the Croatian Science Foundation, aims to determine the stressful conditions under which the population of *Yersinia enterocolitica* 4/O:3 transitions to the VBNC state, as well as the conditions that sustain this state in vitro and in meat.

Project objectives include: establishing a collection of *Y. enterocolitica* 4/O:3 isolates from pig slaughterhouses; determining the factors and their interdependence in the induction and persistence of the VBNC state of *Y. enterocolitica* 4/O:3 using lactic acid in vitro; identifying markers for the VBNC state at the proteomic level; assessing the presence of VBNC *Y. enterocolitica* 4/O:3 after lactic acid meat decontamination and detecting the persistence of VBNC *Y. enterocolitica* 4/O:3 under modified pork storage conditions.

The proposed project involves multidisciplinary research by collaborators with expertise in food microbiology and technology, molecular biology, proteomics, and mass spectrometry. Building on previous research, it will provide key evidence for validating the use of lactic acid in meat decontamination. Overall, it will contribute to understanding the epidemiology of yersiniosis as a leading foodborne disease in Europe.

Keywords: *Yersinia enterocolitica* 4/O:3; VBNC; pork; lactic acid

ADVANCING BEEKEEPING EXPERTISE THROUGH SKILLS LAB TRAINING IN VETERINARY HONEYBEE MEDICINE (EDUCATIONAL ARCHIVE STATION FOR BEEKEEPING AND B-THENET CENTAR CROATIA)

Ivana Tlak Gajger

Faculty of Veterinary Medicine, University of Zagreb, Zagreb, Croatia

e-mail: itlak@vef.unizg.hr

Skills laboratories play a crucial role in educating and training various professionals, particularly those in the field of biomedicine. Education in veterinary honeybee medicine relies on various teaching models to equip students and stakeholders in apiculture with the knowledge and skills needed to ensure honeybee health. These models integrate theoretical knowledge, practical training, and interdisciplinary approaches to address the unique challenges of honeybee veterinary care. The laboratory settings provide a controlled educational environment for participants to safely gain practical, hands-on experience. They allow learners to develop crucial skills in managing hives, rearing queens, and controlling diseases. Training starts with educational models and progresses to vertical learning on live honeybee colonies, ensuring bee health and productivity are never compromised. Furthermore, they incorporate modern tools and technologies, including hive monitoring systems and protective equipment, to ensure adherence to biosecurity measures at the apiary, best practices, and safety standards in the service of One Health. By fostering experiential learning, stakeholders enhance their understanding of bee biology, behavior and the ecological significance of pollinators. Furthermore, they emphasize sustainable practices, such as integrated pest management and habitat conservation, as well as promoting environmental stewardship. B-THENET Centar Croatia, financed by the Horizon Europe Research and Innovation Framework Programme, is part of the Educational archive station for beekeeping at the Faculty of Veterinary Medicine, University of Zagreb, which is dedicated to honeybee veterinary medicine as critical in addressing the health and sustainability of honeybee populations. The exhibition features interconnected sections showcasing effective beekeeping, veterinary practices, and environmental stewardship, all illustrated with descriptive legends. The order of exhibits and educational models is adapted to vertical learning, which allows students to understand the complete content and interconnect individual parts, which is necessary to meet the requirements to work in field and laboratory conditions. The unique beekeeping station offers added value through the parallel display of both archival and contemporary exhibits. This arrangement enhances our understanding of the advancement and modernization of beekeeping technology, as well as the historical methods used to monitor and control bee diseases. By fostering interdisciplinary collaboration and promoting innovations, honeybee veterinary skills labs teach different stakeholders the necessary competencies to enhance honeybee colony health, support sustainable apiculture, and address emerging challenges of pollinator health and biodiversity conservation. Offering various educational initiatives, it represents activities within the B-THENET Center Croatia as part of the project focusing on best practices and innovations for sustainable beekeeping (HORIZON-CL6-2021-GOVERNANCE-01).

Keywords: honeybee colony; One Health; skills lab; Educative-archive station for beekeeping; Faculty of Veterinary Medicine; University of Zagreb

REACHING BEYOND BORDERS: ENHANCING COMMUNICATION AND ENGLISH PROFICIENCY IN VETERINARY MEDICINE EDUCATION - VETCOM

Lada Radin^{1*}, Marko Pećin¹, Zoran Vrbanac¹, Nino Maćešić¹

¹Faculty of Veterinary Medicine Zagreb, University of Zagreb, Croatia

**corresponding author: lada_radin@vef.unizg.hr*

VETCOM is a 24-month Erasmus+ Cooperation Partnership in Higher Education aimed at strengthening the quality and international attractiveness of English-taught veterinary medicine programs in non-English-speaking countries.

The project's main objective is to improve the English language proficiency, communication skills, and pedagogical capacity of teaching and administrative staff involved in English veterinary study programs, thereby supporting the enrolment of international students and the delivery of high-quality veterinary education aligned with EU standards. This will be achieved through the development of a tailor-made English curriculum focused on veterinary terminology and professional communication, harmonisation of syllabi, and digital transformation of teaching and administrative materials.

The partnership brings together Ss. Cyril and Methodius University in Skopje – Faculty of Veterinary Medicine (North Macedonia) as the coordinator, the University of Zagreb – Faculty of Veterinary Medicine (Croatia), with extensive experience in delivering an accredited English veterinary program, and Atlas Language Institute (Ireland), a specialised provider of professional English and teacher training.

Key activities include curriculum development for veterinary-specific English and communication skills, targeted training courses for academic and administrative staff, exchange of practical experience and syllabus alignment with EU-recognised programs, and the translation, adaptation and digitalisation of learning and administrative resources.

Expected results include a tailor-made English curriculum for veterinary higher education professionals, improved English proficiency and communication skills among teaching and administrative staff and harmonised English study programs at partner faculties. The project contributes to the excellence in learning and teaching, support digital transformation, and provides a replicable model for veterinary faculties across Europe.

Keywords: curriculum, veterinary studies, English, Erasmus+

GENETIC FACTORS AND REARING STRESS AS DETERMINANTS OF QUALITY AND FUNCTIONAL INDICATORS IN BEEF MEAT – GEST BEEF

Tomislav Mikuš

Department of Hygiene, Technology and Food Safety, Faculty of Veterinary Medicine University of Zagreb, Croatia

e-mail: tmikus@vef.hr

The preservation and sustainable use of indigenous cattle breeds require an improved understanding of how genetic background and rearing conditions jointly determine meat quality. The GeSt Beef project, financed by the Croatian Science Foundation, investigates genetic factors and rearing stress as key determinants of quality and functional indicators in beef using an integrated, multidisciplinary approach. The study includes two Croatian indigenous breeds – Buša and Boškarin, and the highly selected Salers breed as a comparative reference.

Approximately 300 animals will be sampled in the research. Rearing stress will be assessed throughout the production cycle using animal welfare indicators and multi-matrix cortisol determination (saliva, hair, blood and muscle), allowing evaluation of acute and chronic stress. Meat quality will be characterised through physical and chemical traits, including pH, colour, water activity, lipid oxidation (TBARS), fatty acid and amino acid profiles, and sensory attributes. Functional indicators such as selected vitamins, minerals and oestrogen levels will further define the nutritional value of beef.

Genetic analyses will target polymorphisms in candidate genes related to muscle development, fat deposition and meat quality (e.g. FASN, SCD1, CAPN1, CAST and DGAT1) using PCR-based methods. In parallel, proteomic profiling of selected saliva, serum and muscle samples will be conducted using LC-MS/MS to identify proteins associated with stress response and post-mortem muscle metabolism, aiming to detect novel biomarkers linking stress, genotype and meat quality.

By integrating animal welfare assessment, genetics, proteomics and meat science, GeSt Beef will provide the first comprehensive dataset of this type for Croatian indigenous cattle breeds and support evidence-based strategies for sustainable beef production.

Keywords: indigenous breed, stress, genetics, meat quality, proteomics

SUSTAINABLE MANAGEMENT OF MARINE SENTINEL SPECIES UNDER CUMULATIVE HUMAN ACTIVITIES - SAMESEA

Lada Radin¹, Tomislav Gomerčić², Andrea Gudan Kurilj³, Magdalena Kolenc⁴, Kim Korpes⁴, Ira Topličanec², Martina Đuras^{4*}

¹*EU Funds & Technology Transfer Office, Faculty of Veterinary Medicine University of Zagreb, Croatia*

²*Department of Veterinary Biology, Faculty of Veterinary Medicine University of Zagreb, Croatia*

³*Department of Veterinary Pathology, Faculty of Veterinary Medicine University of Zagreb, Croatia*

⁴*Department of Anatomy, Histology and Embryology, Faculty of Veterinary Medicine University of Zagreb, Croatia*

**corresponding author: martina.duras@vef.unizg.hr*

The SAMESEA project, implemented under the Interreg IPA ADRIION Programme, aims to improve the sustainable management of interactions between human activities and marine sentinel species in the Adriatic–Ionian macro-region. The project addresses current challenges related to fragmented monitoring approaches, uneven implementation of regulations, and insufficient dialogue between economic sectors—such as tourism, fisheries and maritime transport—and marine biodiversity conservation, which is increasingly threatened by pollution, habitat degradation and cumulative pressures. SAMESEA is based on the understanding that without coordinated and sustainable basin-wide management, both marine biodiversity and the socio-economic activities that depend on it will be progressively compromised. Therefore, the project places strong emphasis on transnational cooperation, involving national and regional authorities, research institutions, NGOs and sectoral agencies, in order to foster a shared understanding, capitalization of existing knowledge and long-term collaboration.

The consortium will jointly develop a transnational strategy for monitoring marine sentinel species, test it through pilot actions carried out in different regional contexts, promote good coexistence practices between human activities and marine species, and elaborate an action plan to support more sustainable management of the Adriatic–Ionian basin. Through these activities, partners will apply harmonised monitoring methodologies, exchange experience on coexistence solutions, and strengthen stakeholder networks across the region.

The project is coordinated by CoNISMa – National Interuniversity Consortium for Marine Sciences (Italy). Key partners include Blue World Institute of Marine Research and Conservation and the Faculty of Veterinary Medicine, University of Zagreb (Croatia), Morigenos – Slovenian Marine Mammal Society (Slovenia), Montenegro Dolphin Research (Montenegro), the Ministry of Tourism and Environment (Albania), Archipelagos Institute of Marine Conservation (Greece), CETEOR and the Municipality of Neum (Bosnia and Herzegovina), University “Aleksandër Moisiu” of Durrës (Albania), and the Po Delta Regional Park (Italy), supported by a wide network of associated partners.

Overall, SAMESEA contributes to improved governance, coordinated monitoring and sustainable coexistence between human activities and marine ecosystems in the Adriatic–Ionian region.

Keywords: marine, sentinel species, governance, Adriatic – Ionian region

DIGITAL PLATFORM FOR HISTOLOGY: EDUCATION, RESEARCH, AND OPEN ACCESS (VEF_HISTA+)

Klara Kos^{1*}, Lara Meić¹, Brian Sevin¹, Thomas Daniel Laurent¹, Viera Karaffová², Viera Almašiová², Mirko Tocilj³, Jovana Ivanić¹, Miljenko Bujanić¹, Željana Klječanin Franić¹, Marko Poletto¹, Nikolina Škvorc¹, Lucija Devčić¹, Snježana Kužir¹

¹University of Zagreb, Faculty of Veterinary Medicine, Zagreb, Croatia

²University of Veterinary Medicine and Pharmacy, Košice, Slovakia

³Braća Radić Secondary School, Kaštel Štafilić, Croatia

**corresponding author: kkos@vef.hr*

The VEF_HISTA+ project addresses the pronounced lack of modern digital histological resources, particularly those related to wild animals, as well as terminological inconsistency and the limited availability of open educational materials in the field of veterinary histology. The main objective of the project is to integrate teaching and research through the development of an open digital platform that enhances learning quality, supports research activities, and increases the accessibility of scientific content. The project is financed by the Recovery and Resilience Mechanism (source 581) and is scheduled to be implemented over the 2025–2029 period.

Project activities include efficient management and coordination of an interdisciplinary team. They also encompass the preparation and selection of at least 200 histological specimens from domestic and wild animals, followed by their digitalization using a motorized microscopic scanner and integration into an open-access database on the Cytomine platform. In parallel, a minimum of 20 multimedia educational materials (audio and video lectures, presentations, and quizzes) linked to the digital slides will be developed and made available to students via the learning management system (Merlin) and social media. A particular focus is placed on the development of a multilingual terminological database of histological nomenclature, with definitions in Croatian and translation equivalents in Latin, English, German, and French, thereby contributing to the standardization of professional terminology.

The project includes scientific and pedagogical evaluation of the effectiveness of the digital tools, with results subsequently integrated into the teaching process. Dissemination activities encompass workshops for students, secondary school pupils, and engagement with the local community through events such as Open Days and the Night of Museums. The expected outcomes include a sustainable open digital platform, improved histology teaching, strengthened research capacities, and long-term availability of high-quality educational and scientific resources.

Keywords: veterinary histology, histological terminology, digital education

CONSERVATION MEDICINE – APEX PREDATORS AS SENTINELS OF ECOSYSTEM HEALTH

Magda Sindičić

Faculty of Veterinary Medicine, University of Zagreb, Croatia

e-mail: msindicic@vef.hr

The scientific field of conservation medicine studies the effects of wildlife population ecology on the maintenance and transmission of pathogens and ultimately examines the direct link between the conservation of biodiversity and endangered species with human health. Conservation medicine integrates veterinary medicine, toxicology, epidemiology, public health, ecology, and conservation biology; however, this approach has not yet been applied within the Croatian scientific community. Charismatic apex predators such as the grey wolf (*Canis lupus*) and the Eurasian lynx (*Lynx lynx*) are reliable indicators of ecosystem health and at the same time they strongly attract the attention of both the scientific community and the general public. Therefore, large predators represent an ideal model for the development of conservation medicine in Croatia, for acquiring knowledge on the interactions between pollutants, pathogens, and the ecology of endangered species, and for applying this knowledge to the conservation of ecosystem health shared by humans and animals.

Accordingly, the aim of research project COMPASS (Conservation Medicine – Predators As Sentinel Species), financed by the Croatian Science Foundation (IP-2025-02-1750), is to bring together a multidisciplinary team of experienced experts and early-career scientists and to apply the principles of conservation medicine to the endangered apex predators, the wolf and the lynx. Project will be implemented in the period January 2026 – December 2028. Using innovative research methods, the presence of pollutants and pathogens will be analysed in wolves and lynx tissue samples, and missing data on these threats within the European scientific context will be collected. Finally, hierarchical modelling of species communities (HMSC) will be applied to investigate the correlation of ecological and health parameters of mammals in the study area. We will design and publish a publicly available database, to facilitate the timely publication of information on the presence of pathogens in wild animals in Croatia, as well as archiving and cartographic visualization of data on collected samples, analyses performed, and their results. This database will be available for publication of findings to other experts, so it could potentially develop into a unique medium for monitoring and sharing the data on wildlife diseases in Croatia.

Keywords: *Lynx lynx*, *Canis lupus*, zoonoses, PFAS, toxic trace elements, database

MULTIDISCIPLINARY DEVELOPMENT OF A SCIENTIFICALLY GROUNDED ARTIFICIAL INTELLIGENCE SOLUTION FOR RATIONAL DECISION-MAKING ON READINESS FOR DOG OWNERSHIP AND SUPPORT FOR RESPONSIBLE OWNERSHIP (PK.1.1.12.0130)

Darko Grden^{1,*}, Jelena Gotić¹, Iva Šmit¹

¹Clinic for Internal Diseases, Faculty of Veterinary Medicine, University of Zagreb

**corresponding author: dgrden@vef.unizg.hr*

The project is co-financed by the European Union under the IRI S3 Call. It is implemented from 1. January 2026 to 31. December 2027. The project leader is Agilos IT d.o.o. from Zagreb, while the project consortium consists of the Faculty of Veterinary Medicine, University of Zagreb, and EQUI-VET d.o.o., ensuring a strong integration of technology, science, and veterinary practice.

The objective of the project is to develop an innovative, scientifically grounded AI software solution that enables citizens to objectively and personally assess their readiness for dog ownership and provides support for responsible ownership. The project focuses on preventing impulsive decisions that often result in animal abandonment, while simultaneously improving dog welfare and reducing social and economic costs for the community.

Project activities include experimental development of the AI solution across levels of technological readiness, encompassing interdisciplinary research on the behavior of prospective dog owners, development and training of artificial intelligence models, design of interactive scenarios that simulate real-life ownership responsibilities, and laboratory as well as practical testing and validation of the solution. The Faculty of Veterinary Medicine, University of Zagreb, plays a key role in integrating veterinary expertise, researching dog welfare and behavior, scientific validation of the methodology, and dissemination of results through scientific publications and professional conferences.

The most important project outcomes include a market-ready AI software solution, completed scientific validation and dissemination of results, a feasibility study, protected intellectual property, and the establishment of preconditions for commercialization and international application of the solution. With the support of the European Union, the project represents an example of how artificial intelligence can be used as a tool for making responsible, informed, and sustainable decisions for the benefit of people, animals, and society as a whole.

Keywords: Artificial Intelligence (AI), Responsible Dog Ownership, Readiness Assessment, Animal Welfare, Decision Support Systems

MOLECULAR IDENTIFICATION OF NEMATODES, TAPEWORMS, FLUKES AND OBLIGATE MYIASIS OF DOMESTIC AND WILD ANIMALS (PARKOD, NPOO)

Relja Beck

Croatian Veterinary Institute, Zagreb, Croatia

e-mail: beck@veinst.hr

Nematodes, cestodes and trematodes represent a highly diverse group of parasitic organisms characterised by complex life cycles and a global distribution. They pose a significant burden to animal health and livestock production through substantial economic losses, while also causing a wide spectrum of diseases in humans. Of particular concern are zoonotic species, which remain disproportionately understudied compared with viral and bacterial pathogens, despite their relevance within One Health frameworks. Advances in molecular techniques have revealed extensive genetic diversity within recognised species and uncovered numerous cryptic taxa, fundamentally challenging traditional concepts of parasite taxonomy, host specificity and transmission dynamics. These findings have highlighted the remarkable capacity of parasites to adapt to new hosts and ecological niches. Beyond their direct pathogenic effects, many helminths harbour endosymbiotic microorganisms that may further influence parasite biology, host–parasite interactions and disease outcomes. A specific and understudied group includes obligate myiasis-causing flies, whose larvae migrate through host tissues and organs for most of their developmental cycle, often leading to severe pathological changes. In the Republic of Croatia, comprehensive molecular investigations of nematodes, cestodes, trematodes and obligate myiasis in domestic and wild animals are lacking, as are systematic studies addressing the emergence of antiparasitic drug resistance. Ongoing climate change, environmental alterations, intensified animal trade, evolving husbandry practices, and the rapid spread of invasive vectors and intermediate hosts are profoundly reshaping parasite populations and transmission patterns. The aim of this project is, for the first time in Croatia, to establish an integrated molecular and morphological framework for the investigation of these parasite groups by sequencing multiple genetic markers, correlating molecular data with morphological traits, and characterising associated endosymbionts, thereby providing a robust foundation for future epidemiological, ecological and control strategies.

Keywords: nematodes, cestodes, trematodes, obligate myiasis, domestic animals, wild animals

APICOMPLEXAN AND BACTERIAL TICK-BORNE PATHOGENS IN DOMESTIC RUMINANTS, HORSES AND HAEMATOPHAGOUS VECTORS (ABAVEC, HRZZ IP-2022-10-7842)

Relja Beck

Croatian Veterinary Institute, Zagreb, Croatia

e-mail: beck@veinst.hr

Ticks are currently recognised as the most important arthropod vectors affecting animals worldwide, and the incidence of tick-borne infections (TBIs) is expected to increase further as climate change promotes tick survival, activity and geographic expansion. Within the framework of the previous GENOTICKRECK project, we detected a wide range of tick-borne pathogens and genotypes of major veterinary relevance in ticks, including *Anaplasma ovis*, *A. phagocytophilum*, *Ehrlichia canis*, *Ehrlichia* sp., “*Candidatus Neoehrlichia lotoris*”, *Babesia canis*, *B. vulpes*, *B. microti*, *B. venatorum*, *Babesia* sp. “Badger type A” and “Badger type B”, *B. ovis*, *Babesia* cf. *crassa*, *Babesia* sp. “tavsan”, *Theileria ovis*, *T. orientalis*, *T. equi*, *T. capreoli*, *Hepatozoon canis*, *H. felis* and *Hepatozoon* “Badger type”.

Diseases that were previously confined to tropical or subtropical regions are now increasingly reported in temperate areas, including Europe. In this context, anaplasmosis and piroplasmosis are associated with considerable economic losses in livestock production and represent an important animal welfare concern. In parallel, haemotropic *Mycoplasma* spp. have emerged over the last decade as neglected but clinically relevant pathogens affecting a broad range of animal hosts. Fatal cases of *Anaplasma marginale* infection and *Theileria orientalis*/*Anaplasma bovis* co-infections in Croatian cattle have raised critical questions regarding the presence, infection rates, geographical distribution, health impact and genetic diversity of tick-borne pathogens and their vectors.

Despite their clear economic and veterinary importance, data on the occurrence, prevalence and distribution of these pathogens in small ruminants, cattle and horses remain scarce. Furthermore, transmission pathways, particularly the role of ticks and other haematophagous vectors, are still poorly understood. The proposed project aims to address these knowledge gaps by investigating apicomplexan and bacterial tick-borne pathogens in domestic ruminants and horses, assessing their impact on animal health, and exploring their presence in ticks and other blood-feeding insects. By integrating clinical examinations, molecular diagnostics, epidemiological analyses and phylogenetic approaches, this multidisciplinary study will provide novel insights into the ecology, transmission and veterinary relevance of these still neglected pathogens.

Keywords: *Anaplasma* spp., *Ehrlichia* spp., *Babesia* spp., *Theileria* spp., *Hepatozoon* spp.

ROUND TABLE

ROUND TABLE: SOCIAL SCIENCES AND HUMANITIES IN HIGHER VETERINARY EDUCATION

Željana Klječanić¹, Ivana Franić², Željka Kamenov², Snježana Kužir¹, Jovana Ivanić¹, Iva Lehunšek Panić¹, Marko Poletto¹

¹ Faculty of Veterinary Medicine, University of Zagreb, Zagreb, Croatia

² Faculty of Humanities and Social Sciences Zagreb, Zagreb, Croatia

In contemporary higher veterinary education, the importance of integrating biomedical sciences with social sciences and humanities is increasingly recognised. The Round Table on Social Sciences and Humanities in Higher Veterinary Education will address the role of these disciplines in educating doctors of veterinary medicine and in lifelong learning. Particular emphasis will be placed on defining the core elements of quality pedagogical practice in higher education, as well as on pedagogical and communication tools for digital generations. Discussions will include the use of artificial intelligence tools in veterinary medicine through their integration into learning and professional practice, e-learning as a key context for interdisciplinary teaching and the internationalisation of studies, and the development of transversal skills. The debate will examine the role of terminological and library resources and information specialists in supporting the teaching process, the integration of specialised language into bilingual instruction and multilingual environments, and the development of critical thinking and ethical awareness through humanistic content. The aim is to view social sciences and humanities not merely as auxiliary fields but as an integral part of veterinary education that, by fostering interdisciplinarity, strengthens the professional, communicative, and pedagogical profile of future veterinarians.

Keywords: higher veterinary education, pedagogical tools, communication skills, educational materials, terminological and library resources, e-learning

ROUND TABLE: THE SCANDINAVIAN MODEL OR A MONOGRAPH – THAT IS THE QUESTION NOW?

Assoc. Prof. Magda Sindičić, DVM, PhD

Department of Biology and Pathology of Wildlife, Faculty of Veterinary Medicine, University of Zagreb, Croatia

The round table aims to provide support and information to PhD students in Veterinary Science. The University of Zagreb allows two forms of doctoral dissertations: a scientific monography and the Scandinavian model. Choosing the appropriate form of doctoral dissertation, as well as the procedure for applying for, evaluating, and approving the doctoral research proposal, often presents difficulties for doctoral students.

Therefore, in the introductory part, Vedrana Pšenica, an employee of the Office for Postgraduate Studies, will present the specific features and differences between the scientific monograph and the Scandinavian doctoral model, as well as the administrative workflow for each model. This will be followed by short personal accounts from Dr. Iva Benvin and Dr. Ivana Sabolek, senior assistants who have recently defended their doctoral dissertations.

The discussion will include the following panelists: Vedrana Pšenica, as a representative of the Office for Postgraduate Studies of the Faculty of Veterinary Medicine, University of Zagreb; Prof. Alen Slavica, PhD, as a representative of the Doctoral Study Council; Dr. Relja Beck as a representative of mentors; and Dr. Iva Benvin and Dr. Ivana Sabolek as representatives of doctoral students. The discussion will be moderated by Assoc. Prof. Magda Sindičić, PhD.

Based on participants' questions and through discussion and exchange of experiences, we will jointly identify the advantages and disadvantages of each doctoral model in relation to the goal of the dissertation and the specific research conditions. The final goal will be to formulate proposals for improving the process of application, evaluation, and approval of doctoral research proposals, which will be forwarded to the Management of the Faculty of Veterinary Medicine and to the University of Zagreb.

Keywords: PhD, Scandinavian model, monography

ROUND TABLE: CHALLENGES IN VETERINARY PRACTICE TODAY

Jelena Gotić, Elizabeta Pongrac

Clinic for Internal Diseases, Faculty of Veterinary Medicine, University of Zagreb, Zagreb, Croatia

The Round Table *Challenges in Veterinary Practice Today* aims to open a structured and professionally grounded discussion on mental health, stress, and sustainability within the veterinary profession. Contemporary veterinary work extends far beyond clinical expertise and includes high client expectations, administrative and financial pressures, staff shortages, ethical dilemmas, and constant emotional responsibility. Prolonged exposure to such conditions places veterinarians at increased risk of chronic stress and burnout.

In the introductory part, the moderators will outline the key psychological and organisational challenges currently recognised in veterinary medicine, including emotional exhaustion, moral distress, and the normalisation of overload within professional culture. The discussion will then proceed through thematic rounds addressing major sources of stress in daily practice; relationships with animal owners and the boundary between empathy and emotional exhaustion; the emotional and ethical burden of euthanasia; and prevention, leadership responsibility, and institutional support.

The panel will bring together representatives of different professional perspectives: referral clinical practice, practice management and leadership, professional chamber governance, and psychiatry. Through the exchange of Croatian and international experiences, participants will analyse how stress manifests at individual and organisational levels, how complaint procedures and regulatory frameworks influence professional wellbeing, and how communication protocols and team culture can mitigate risk.

Based on questions from the audience and shared professional experiences, the discussion will seek to identify realistic and immediately applicable measures to strengthen psychological safety, reduce stigma around seeking help, and improve support systems within practices, professional bodies, and the educational system. The final goal is to formulate concrete proposals that contribute to a healthier, more resilient, and professionally sustainable future for veterinarians.

Keywords: mental health, burnout, chronic stress, psychological safety and prevention